

# Ultrasound versus X-Ray Abdomen in the diagnosis of Fibro-Calculous Pancreatic Diabetes

S. SURESH, V. MOHAN, INDRANI SURESH, A. RAMACHANDRAN, G. VIJAYA KUMAR,  
C. SNEHALATHA, M. VI SWANATHAN

## SUMMARY

Fibrocalculous Pancreatic Diabetes is a form of diabetes secondary to chronic, non-alcoholic, pancreatitis. The usefulness of ultrasonography versus plain X-Ray of the abdomen in the diagnosis of this entity was compared. The sensitivity of the ultrasound for picking up of pancreatic calculi was 83.8% compared to 95.2% for plain X-Ray abdomen. However 23% of patients in whom X-Ray's were normal ultrasonography picked up evidence of chronic pancreatitis. The diagnosis of chronic pancreatitis in these patients was confirmed by exocrine pancreatitis function tests. Ultrasonography had a false negative rate of 10.2%. In conclusion plain X-Ray of the abdomen and ultrasonography are complementary to each other in the diagnosis of fibrocalculous pancreatic diabetes. A combination of both parameters along with a test of exocrine pancreatic function greatly reduces the need for invasive procedures for the diagnosis of this disease.

Fibro-Calculous Pancreatic Diabetes (FCPD) is a unique form of diabetes that is peculiar in that it is exclusively found in tropical countries<sup>1</sup>. The diabetes in FCPD is second-

dary to tropical chronic pancreatitis<sup>2</sup>. Southern India has by far the highest prevalence of FCPD in the world<sup>3-4</sup>. The two characteristic features of this disorder as the name itself implies is the presence of fibrosis as well as the occurrence of calculi in the pancreas<sup>5</sup>. An earlier study by Mohan et al<sup>6</sup> had shown some of the characteristic features of this entity on ultrasonography. However in that study small numbers of patients had been studied and no comparison between the relative usefulness of Ultrasound and X-Ray in the diagnosis of this entity was made. In this study we report on a large series of FCPD patients and compare the relative efficacies of these two modalities in the diagnosis of this condition.

## MATERIALS AND METHODS

The patients comprised of those attending the Diabetes Research Centre and M.V. Hospital for Diabetes, Madras a large referral centre for diabetes with an annual registration of over 5000 new diabetic patients. The study group consists of 161 patients who were seen during the period from October 1 1986 to April 15 1988 in whom simultaneous X-Ray and ultrasonographic studies could be carried out.

All these patients were clinically suspected to have possible Fibro-Calculous Pancreatic Diabetes based on one or more of the following characteristics: a) young age at diagnosis, b) insulin requiring diabetes but absence of ketosis, c) history suggestive of malabsorption and d) Leanness or evidence of overt protein calorie malnutrition.

All patients underwent a complete biochemical work-up at the Diabetes Research Centre. This included oral glucose tolerance tests, glycosylated haemoglobin estimations, lipid studies and kidney function tests. The patients were then referred to a radiological institute where after adequate preparation a plain X-Ray of the abdomen (AP view) focussing on the L1 vertebra was taken to rule out pancreatic lithiasis. The X-Rays were reported by a senior radiologist who was totally unaware of the clinical status of the patient. All patients then went on to have an ultrasonogram of the abdomen at the Mediscan Systems, Madras for evaluation of the pancreas. All sonograms were done by the same individuals (SS and IS). The sonologists also were completely unaware of the clinical status of the patients. All the patients were scanned with the same machine (ATL ULTRAMARK 8 - real time mechanical sector scanner) using the same transducer frequency 3.5 MHz. The sonographic features of the pancreas were studied under the following heads:

- 1) Echogenicity of the gland which was marked as a) Hypoechoic if the echogenicity was less than the liver b) Moderately echogenic if the echogenicity was equal to or slightly more than the liver and c) Hyperechoic if the echogenicity was markedly more than the liver and equal to the retroperitoneal fat
- 2) Contours of the gland
- 3) Pancreatic duct morphology and its size
- 4) Calculi in the duct and

## 5) Calcification in the parenchyma.

After sonographic evaluation, these findings were compared with radiological findings. In cases where there was a discrepancy between the results of the radiological and ultrasonographic studies, exocrine pancreatic function studies were carried out. This consisted of faecal chymotrypsin estimation which is a reliable index of chronic pancreatitis<sup>8</sup>.

Plasma glucose was estimated by the glucose oxidase method (Boehringer Mannheim, W. Germany). Glycosylated haemoglobin was estimated by a colorimetric method<sup>9</sup>. Faecal chymotrypsin was estimated by an enzymatic method<sup>10</sup> (Boehringer Mannheim, W. Germany).

## RESULTS

A total of 161 diabetic patients underwent X-Ray and ultrasonographic studies of the pancreas to look for evidence of chronic pancreatitis. In 80 patients both X-Ray and ultrasonography were normal and these patients were excluded from the study. In three patients the X-Ray appearance of 'calculi' turned out to be artefacts. These patients were also excluded from the study. The remaining 78 patients were reported to have either X-Ray or ultrasound evidence of chronic pancreatitis.

Pancreatic calculi were reported as being present both on X-Ray and ultrasound in 49/78 patients (62.8%). In 3 patients calculi missed on X-Ray were picked up on ultrasonography. In 10 patients calculi seen on X-Ray were missed by the ultrasound. Thus a total of 62 patients had evidence of pancreatic calculi either on X-Ray or ultrasound in this series. The sensitivity of the ultrasound for picking up of pancreatic calculi was 52/62 cases (83.8%). The sensitivity of the X-Ray for pick-

ing up of calculi was 59/62 cases (95.2%). In 2 of the 10 patients in whom the ultrasound missed the pancreatic calculi, other features of chronic pancreatitis were made out. In the other 8 patients the ultrasound was reported as normal. Thus if ultrasonography had been used as the single tool for diagnosis of chronic pancreatitis the false negative rate would have been 8/78 (10.2%).

As already mentioned, of the 19 patients in whom X-Ray was normal, calculi were picked up on ultrasound in 3 patients. In the remaining 16 patients, ultrasonography

demonstrated unequivocal evidence of chronic pancreatitis such as fibrosis of the gland, increase in echogenicity of the gland, ductal dilatation etc (Table I). Twelve of these 16 patients had low faecal chymotrypsin levels. In the other 4 patients the faecal chymotrypsin levels were within the normal range. Thus if X-Ray alone was used for the diagnosis of FCPD, the false negative rate would have been 19/78 patients (24.3%).

Figure 1 shows a plain X-Ray of the abdomen showing large pancreatic calculi in the head region of the pancreas.

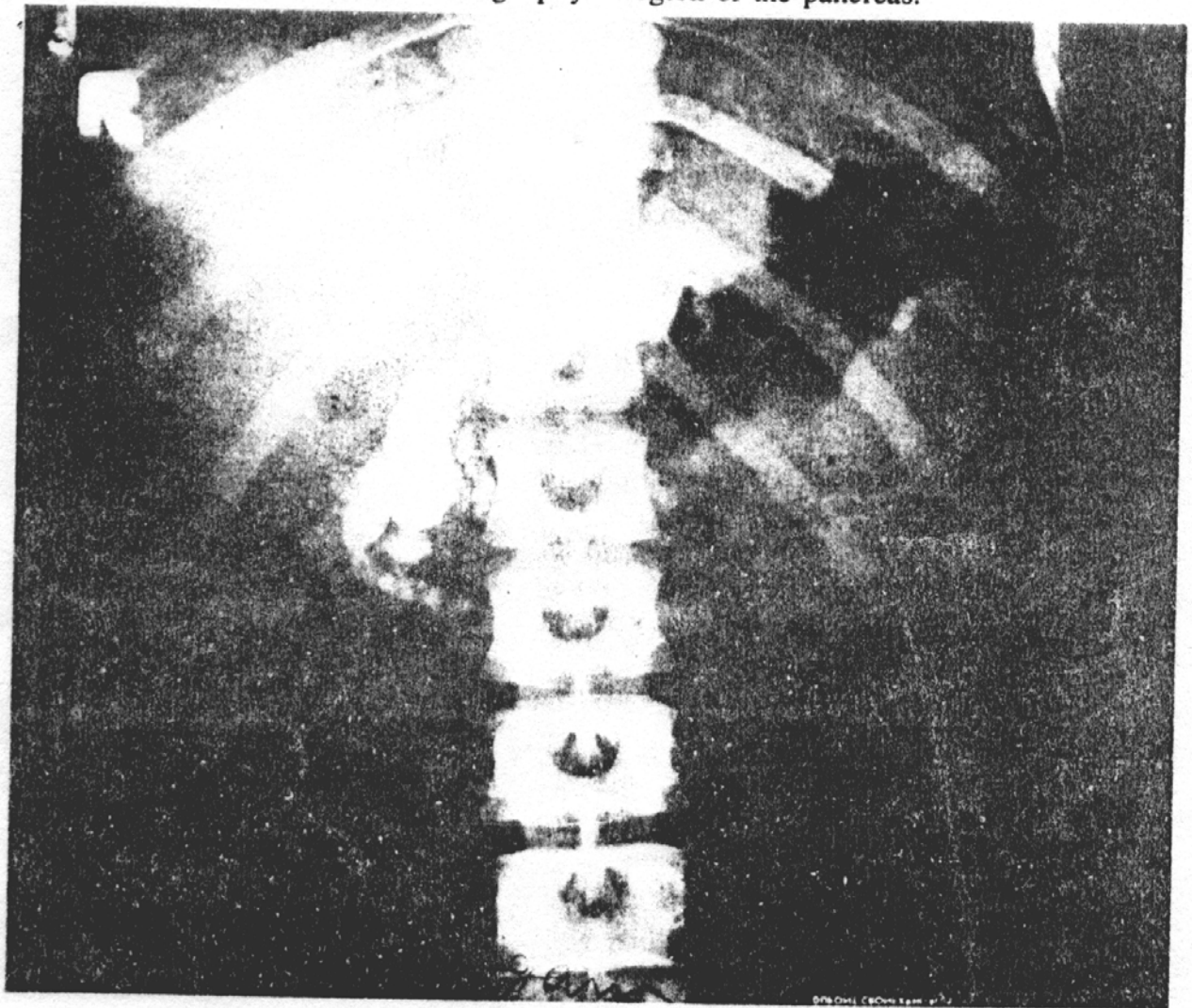


Figure 1.

Figure 2 shows the ultrasound of a patient with FCPD (noncalcific variety). Note the marked increase in the echogenicity of the pancreas.

Figure 3 shows ultrasound of an FCPD patient with calculi. Note the markedly dilated pancreatic duct with intraductal calculi.

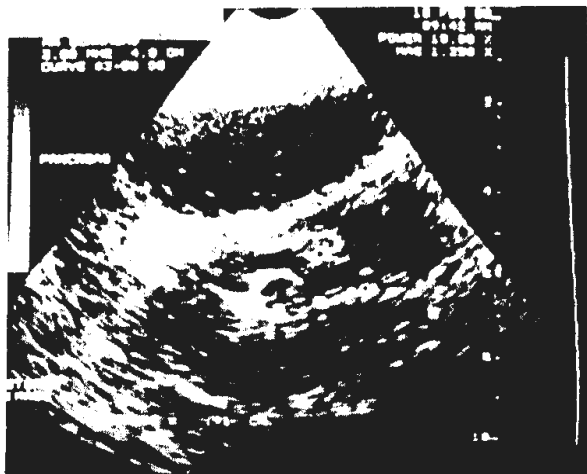

Figure 2.



Figure 3.

## DISCUSSION

The diagnosis of chronic pancreatitis is often a very difficult one. The hallmark of chronic pancreatitis is the presence of pancreatic calculi<sup>11</sup>. However the frequency of pancreatic calculi varies between 25-80% in cases of chronic pancreatitis<sup>12</sup>. When pancreatic calculi are present, a plain X-Ray of the abdomen after careful preparation is often good enough to make the diagnosis of chronic pancreatitis. As seen in this study the pick up rate of pancreatic calculi by X-Ray is better than ultrasound (95.2% Vs.83.8%). The usefulness of the ultrasound even in this situation is shown by several observations made in this study. In three cases the X-Ray reported small 'calculi'. A normal ultrasound prompted us to do a repeat X-Ray in these cases. The repeat X-Rays showed that they were in fact calcification of the costo-chondral junction in two cases. In the third case the artefact, probably a faecolith, disappeared on repeating the X-Ray. Ultrasound also has the advantage that the calculi can be accurately localised to the pancreas. Occasionally gall stones, kidney stones or calcified lymph nodes seen on X-Ray may be mistaken for pancreatic calculi. In one of our patients what appeared to be a pancreatic calculi on X-Ray turned out to be calcification of the wall of a pseudopancreatic cyst on ultrasonography. Finally in 3 patients in whom X-Ray missed pancreatic calculi they

were picked up on ultrasonography. In these three cases the diagnosis of chronic pancreatitis was confirmed not only by the presence of other markers of the disease such as ductal dilatation etc. but also by the faecal chymotrypsin studies. Thus if X-Ray alone was used for the diagnosis, 4.8% of patients with pancreatic calculi would have been missed. Besides several false positives would have been reported.

It has already been mentioned that in many cases of chronic pancreatitis, pancreatic calculi are absent. This study demonstrates that ultrasonography has distinct advantages over X-Ray in such cases. In this series 24.3% of patients had evidence of chronic pancreatitis on ultrasonography in the absence of pancreatic calculi on X-Ray. In the majority of these cases the diagnosis of chronic pancreatitis was established by the use of pancreatic function studies. In a few cases with ultrasound evidence of chronic pancreatitis, the faecal chymotrypsin test was negative. Unfortunately even the faecal chymotrypsin test has a sensitivity only of about 85%<sup>13</sup>. Thus

TABLE I

Ultrasonographic features of chronic pancreatitis in the 16 non-calcific cases

Non-homogenous appearance	—	16 cases
Increased echogenicity	—	15 cases
Decreased echogenicity	—	1 case
Irregular contours/margins	—	9 cases
Dilated pancreatic duct	—	2 cases

it is not possible to establish whether the 4 patients with positive ultrasound but negative faecal chymotrypsin tests are false positives, or indeed, are early cases of chronic pancreatitis. Perhaps the use of ERCP, histopathology or other invasive procedures would have helped resolve this but they were not done for ethical reasons.

This study is interesting in several respects. This is the first report of a comparison between X-Ray and ultrasonography in FCPD patients. All earlier studies on this aspect had been done in western countries where the etiology of chronic pancreatitis is usually due to alcoholism<sup>11-13</sup>. Since the frequency of pancreatic calculi varies in alcoholic and non-alcoholic chronic pancreatitis, the results obtained in this study cannot be compared to the figures reported from western countries. Secondly considering that FCPD is a relatively rare disease, large numbers of patients have been studied. Thirdly consecutive FCPD patients were studied to eliminate selection bias. In this respect the present study differs from our earlier report<sup>6</sup> where only those with severe disease were referred for the ultrasonographic studies.

In summary, ultrasonography and X-Ray appear to be complementary to each other in the diagnosis of FCPD. While the ultrasound has a slightly lower sensitivity for pick up of calculi, its ability to pick up morphological abnormalities in the pancreas make it a very useful diagnostic tool for this condition. We recommend that an X-Ray of the abdomen should be routinely done in all patients with suspected FCPD. In cases with doubtful calculi or if the X-Ray is negative but the clinical suspicion is still high, ultrasonography would be an useful additional tool in the diagnostic work up of patients with FCPD. The addition of a third parameter namely the pancreatic exocrine function test such as faecal chymotrypsin or Lundh meal, PABA test etc. considerably reduces the need for more invasive investigations for the diagnosis of chronic pancreatitis. Such investigations may therefore be reserved for early cases where all

other tests are negative or when controversial results are obtained by other tests.

#### ACKNOWLEDGEMENT

The authors wish to thank M/S Boehringer Mannheim, W. Germany for the gift of the faecal chymotrypsin kits used in this study.

#### REFERENCES

- 1) WHO study group report on diabetes mellitus: World Health Organisation. Technical report series No. 27, Geneva, 1985.
- 2) Geevarghese PJ: Calcific Pancreatitis. Bombay, Varghese Publishing Company, 1985.
- 3) Viswanathan M.: Pancreatic diabetes in India- an over view. In: secondary diabetes- the spectrum of diabetic syndromes. Podolsky S, Viswanathan M (Eds). New York, Raven Press, 105, 1980.
- 4) Mohan V et al.: Pancreatic diabetes in south India: Heterogeneity in clinical and biochemical profile. *Diabetologia* 28; 229-232, 1985.
- 5) Nagalotimath S.J.: Pancreatic pathology in pancreatic calcification with diabetes. In: Secondary diabetes- the spectrum of the diabetic syndromes. Podolsky S, Viswanathan M (Eds). New York, Raven Press, 117 1980.
- 6) Mohan V, Sreeram D, Ramachandran A, Viswanathan M, Doraiswamy KR.: Ultrasonographic evaluation of the pancreas in tropical pancreatic diabetes. *Acta Diabetologica Latina* 22; 143-148, 1985.
- 7) Metreweli C: Practical abdominal ultrasound. London, Heinemann, 96, 1978.
- 8) Ammann R, Akovbiantz A, Hacki W, Largiader F, Schmid M.: Diagnostic value of the faecal chymotrypsin test in pancreatic insufficiency particularly chronic pancreatitis. *Digestion* 21; 281-289, 1981.
- 9) Eross J et al.: Colorimetric measurement of glycosylated protein in whole blood, red blood cells, plasma and dried blood. *Ann. Clin. Biochem.* 21; 519-522, 1984.
- 10) Bode C, Bode JC.: Usefulness of a simple photometric determination of chymotrypsin activity in stools: results of a multicentric study. *Clin. Biochem.* 19; 333-337, 1986.
- 11) Sarles H.: Epidemiology and pathophysiology of chronic pancreatitis and the role of pancreatic stone protein. *Clin. Gastroenterol.* 13; 895-912, 1985.
- 12) Bank S.: Alcoholic and non-alcoholic chronic pancreatitis: differences in natural history? (Editorial). *Pancreas* 2; 365-367, 1987.
- 13) Ammann RW, Buehler H, Muench R, Freiburghaus AW, Seigenthaler W.: Differences in the natural history of idiopathic (nonalcoholic) and alcoholic chronic pancreatitis. A comparative long-term study of 287 patients. *Pancreas* 2; 368-377, 1987.