

J. Kalita
U. K. Misra

Neurophysiological studies in acute transverse myelitis

Received: 31 August 1999
Received in revised form: 12 June 2000
Accepted: 28 June 2000

Abstract A systematic evaluation of anterior horn cell, motor and sensory pathways is possible by electromyography (EMG), motor (MEPs) and somatosensory (SEPs) evoked potentials, respectively, which may provide valuable information on acute transverse myelitis (ATM). In a prospective hospital-based study, EMG, MEP and SEP studies were carried out on admission and after 3 months in 39 patients with ATM. All the patients also underwent detailed clinical evaluation, and spinal magnetic resonance imaging (MRI) was performed in 28. Outcome was defined at the end of 3 months as poor, partial or complete recovery on the basis of functional status. Spinal MRI revealed hyperintense signal changes in T2 extending for two segments to the entire spinal cord. Central motor conduction time to tibialis anterior (CMCT-TA) was more frequently abnormal (90%), followed by tibial SEP (77%). CMCT to abductor digiti

minimi (ADM) was abnormal in 30% and median SEP in 15% of patients. Evidence of denervation on EMG was present in 51% of patients. The CMCT-TA improved in 48% patients and tibial SEP in 32%. Median SEP improved in all patients, and CMCT-ADM remained prolonged in two. At 3 months 2 patients had died, and 18 had poor, 10 partial and 9 complete recovery. CMCT was correlated with muscle power, tone, reflex and MRI changes. Patients' outcome of was correlated with CMCT, SEP and EMG. These results are consistent with pronounced involvement of dorsal region of spinal cord in ATM. MEP is more frequently abnormal than SEP.

Key words Transverse myelitis · Motor evoked potentials · Somatosensory evoked potentials · Electromyography · Prognosis · Magnetic resonance imaging

J. Kalita (✉) · U. K. Misra
Department of Neurology,
Sanjay Gandhi PGIMS,
Lucknow-226014, India
Fax: 91-522-440973/259973
e-mail: jkalita@sngpi.ac.in

Introduction

Both grey and white matter may be affected to a variable extent in acute transverse myelitis. The involvement of grey matter can be monitored by electromyography (EMG) and that of white matter by somatosensory (SEP) and motor evoked potentials (MEPs). The distribution of EMG and evoked potential changes has been reported in a limited manner in a few studies [4, 7, 10]. These studies were limited either by evaluating only median SEP [4] or being

carried out in only a small number of patients [10]. The distribution and pattern of neurophysiological changes and their relationship with the clinical and radiological findings have not been reported. In this communication we report the neurophysiological findings in the patients with ATM and the correlations the initial electrophysiological changes with clinical findings and outcome.

Patients and methods

Patients

This study was carried out in 39 patients treated by us between 1993 and 1998 for ATM (29 males, 10 females; mean age 35 years, range 9–70). A history of fever was present in 13 and diarrhoea in 1. All patients had lower limb weakness, sensory loss and bladder dysfunction. The symptoms peaked within 1 week in 23, 2 weeks in 9, and 4 weeks in 2 patients. Upper limb weakness was noted in 12 patients, which was mild in all except 2. One patient had respiratory paralysis, who had severe upper limb weakness as well. On admission lower limb weakness of grade 0 was present in 30, grade I or II in 4 and grade III or IV in 5. Lower limb tone was reduced in 25 and increased in 9; upper limb tone was increased in 5 and reduced in 2. Knee and ankle reflexes were reduced in 29 and increased in 10. The upper limb reflexes, however, were increased in 7 and reduced in 3. Horizontal level of sensory loss was present in all patients. Most of the patients had loss at the dorsal level ($n=32$) followed by the lumbar ($n=6$) and the cervical ($n=1$).

The diagnosis of ATM was based on the criteria of Jeffery et al. [5] which include (a) acutely or subacutely developing motor, sensory and sphincter disturbance; (b) spinal segmental level of sensory disturbance with well defined upper limit; (c) no clinical or laboratory evidence of spinal cord compression; (d) absence of other known neurological diseases such as syphilis, previously diagnosed multiple sclerosis, neoplasm, spinal cord arteriovenous malformation, sarcoidosis or HIV infection; and (e) lack of clinical progression beyond 4 weeks [5].

In all the patients a detailed neurological examination was carried out. Weakness was evaluated by the Medical Research Council (MRC) scale and tone by Ashworth scale. Tendon reflex, plantar response and sensory abnormalities were also recorded. Spinal magnetic resonance imaging (MRI) was carried out in 28 patients on a 2.0-T superconducting system operating at 1.5 T using a flat oval surface coil. All images were obtained employing multislice spin echo sequences which included gradient motion rephasing to reduce motion induced artefacts. T1, T2 and proton density spin echo sequences were obtained in sagittal plain with slice thickness of 3 mm, interslice gap 0.3 mm and 220/256x256 matrix. The whole spinal cord imaging was completed in two to three examinations. Spinal MRI revealed hyperintense signals on T2 in all but two patients in whom signal changes extended by a mean of ten segments (from two to the entire spinal cord).

Neurophysiological investigations included nerve conduction study of peroneal and sural, concentric needle EMG, median and tibial SEP and MEP studies to upper and lower limbs bilaterally.

Concentric needle EMG was carried out after 2 weeks of illness in a number of muscles of upper and lower limbs such as abductor pollicis brevis, first dorsal interossei, brachioradialis, biceps, deltoid, vastus medialis, tibialis anterior (TA) and gastrocnemius. The presence of fibrillation and sharp waves was noted. MEPs were visually analysed for duration, amplitude, phase and recruitment pattern.

Median SEPs were obtained by stimulating median nerve at the wrist by a 0.1 ms square wave pulse at 3 Hz at an intensity to provide a painless twitch of the thumb. Active surface recording electrode was placed at Erb's point and at contralateral parietal cortex 3 cm behind and 7 cm lateral to vertex using a midfrontal reference. For tibial SEPs posterior tibial nerve was stimulated below the medial malleolus at 3 Hz sufficient to produce a painless twitch of the great toe. The recording electrode was placed at the spinous process of the first lumbar vertebra (L1) and 2 cm caudal to Cz (Cz'). The reference electrode was placed at L3 and Fz. The impedance of electrodes was kept below 5 k Ω , frequency bandpass was 2000–3000 Hz and analysis time 100 ms. A total of 512 responses were twice averaged to ensure reproducibility at a gain of 1–2 μ V division. Median SEPs were analysed by the latency of N9 and N20 and interpeak latency of N9

and N20. For tibial SEPs the latency of N21, P40 and N21-P40 central sensory conduction time (CSCT) were measured [10].

MEPs were recorded from both upper and lower limbs bilaterally following transcranial electrical stimulation of cerebral cortex and spine. A digitimer D180 delivering electrical shock up to 750 V with a time constant of 50–100 μ s was used. The stimulating electrode was a 1-cm-diameter saline-soaked felt pad mounted on a plastic handle. To activate abductor digiti minimi (ADM), the cathode was placed at the vertex and anode 7 cm laterally and 1 cm anterior to a line drawn from vertex to tragus. For activating TA the anode was kept at the vertex and cathode 7 cm posterior. For cervical and lumbar stimulation, the cathode was placed below the spinous process of the seventh cervical (C7) and 12th thoracic vertebrae (T12) and the anode proximally. MEPs were recorded by surface electrodes placed on ADM or TA in a belly tendon montage. During the cortical stimulation the patient was asked to relax. The EMG were filtered through 20 Hz–2 KHz at a gain of 0.5–1 mV division. The stimulus intensity was 90–100% for cortical and 50–60% of maximum output for spinal stimulation. Three responses were obtained at 10-s intervals, and the one with the shortest latency was recorded. Onset latency and the amplitude of the negative phase were recorded. Central motor conduction time was calculated for the upper limb (CMCT-ADM; performed in all patients) by subtracting the latency on C7 stimulation from that on cortical stimulation and that for the lower limb (CMCT-TA; performed in 33 patients) by subtracting the latency on L1 stimulation from that on vertex stimulation. The results were compared with the normal values of our laboratory [10].

Haemoglobin, blood counts, erythrocyte sedimentation rate, blood chemistry, serum test for syphilis, HIV, rheumatoid factor and anti-nuclear antibodies were studied in all the patients. Cerebrospinal fluid was examined for protein, sugar, cell, bacteria and fungi. The outcome was defined into poor (bed ridden), partial (partial dependence for activities of daily living) and complete (independent for daily activities) at the end of 3 months. The neurophysiological changes were compared with clinical and radiological changes employing the χ^2 test.

Results

CMCT-TA was the most frequently abnormal measurement (90% of cases) followed by tibial SEP (77%), CMCT-ADM (30%) and median SEP (15%). CMCT-TA was abnormal in all but four patients, and CMCT-TA was abnormal in ten patients. CMCT-TA was unrecordable in 25 patients (49 sides) and prolonged in 11 patients (19 sides) whereas CMCT-ADM was unrecordable in 3 patients (5 sides; Fig. 1a) and prolonged in 8 patients (12 sides). SEPs were less frequently abnormal. Tibial SEPs were carried out in all and median SEPs in 33 patients. Tibial SEPs were abnormal in 30 patients. Tibial CSCT was unrecordable in 25 patients (47 sides; Fig. 1b) and prolonged in 6 patients (7 sides). Median SEP was unrecordable in 3 patients (5 sides), and CSCT was prolonged in 3 patients (4 sides). Evidence of denervation on concentric needle EMG was present in 20 patients, which was found in the lower limb muscles in all but three who had fibrillations in upper limb muscles as well. These patients had severe upper limb weakness. The initial and final neurophysiological results are summarised in Table 1.

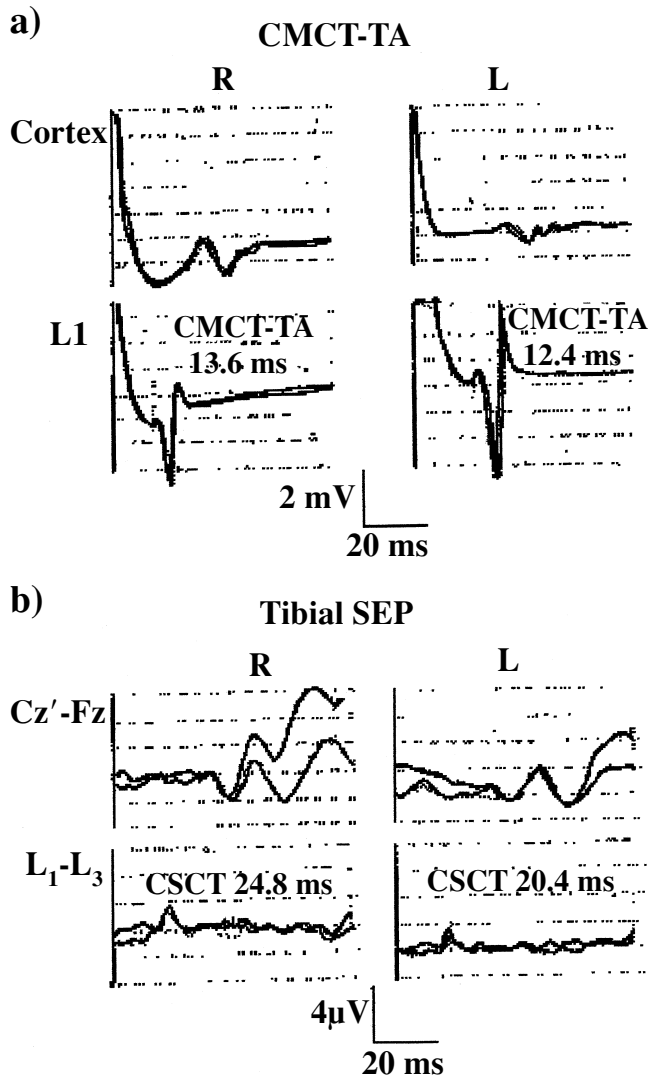


Fig. 1. **a** Central motor conduction time to tibialis anterior (*CMCT-TA*) was unrecordable initially (not shown) but became normal at 3-month follow-up. **b** Tibial SEPs were unrecordable initially which became normal at 3-month follow-up. This patient (no. 17) improved completely by 3 months. *CSCT* Central sensory conduction time, right; L left

Follow-up

At 3 months 2 patients had died during the acute stage due to respiratory paralysis, 18 patients had poor, 10 partial and 9 had complete recovery. The lower limb power improved in 24 patients; the improvement was of 4 MRC grade in 8, 3 grade in 6, 2 grades in 2, and 1 grade in the remaining patients. Spasticity persisted to in upper limbs in 2 patients. In the lower limbs flaccidity persisted in 14; in the remaining patients tone was increased in 16 and normal in 7 patients. The tendon reflexes in the upper limb continued to be exaggerated in 2 patients. Knee and ankle reflexes were reduced and exaggerated in 16 patients each and normalised in the remaining patients.

Joint position sensation improved in 10 patients. The evoked potential changes could be repeated only in 22 patients, and improvement was noted in 17. Initially unrecordable *CMCT-ADM* became normal in one patient and remained prolonged in another. Initially prolonged *CMCT-ADM* normalised in all the patients. *CMCT-TA* revealed more frequent changes; initially unrecordable *CMCT-TA* became normal in 6 patients and remained prolonged in 3 patients. Initially prolonged *CMCT-TA* normalised and improved although still prolonged in 4 patients each. SEPs revealed less frequent changes in ATM patients. Initially unrecordable median SEP became normal in one patient and prolonged N9-N20 conduction time improved to normal in two. Initially unrecordable tibial SEP normalised in four patients and remained prolonged in one. Initially prolonged tibial CSCT normalised in two. The changes in evoked potentials are summarised in Table 2. Initial *CMCT-TA* measurements were correlated with tone ($c^2=20.04$, $df=4$, $P < 0.01$), reflex ($c^2=15.79$, $df=4$, $P < 0.01$), muscle power ($c^2=20.72$, $df=4$, $P < 0.01$) and MRI changes ($c^2=6.0$, $df=4$, $P < 0.05$). Patients' outcome was correlated with initial *CMCT-TA* ($\chi^2=29.32$, $df=4$, $P < 0.01$), SEP ($\chi^2=32.62$, $df=4$, $P < 0.01$) and EMG changes ($\chi^2=22.08$, $df=2$, $P < 0.01$). The extent of MRI changes was not correlated with initial SEP abnormalities or outcome.

Table 1 Distribution of neurophysiological findings in initial and at 3 months follow-up in patients with acute transverse myelitis (*CMCT-ADM* central motor conduction time to abductor digiti minimi, *TA* tibialis anterior, *SEP* somatosensory evoked potential potential, *NR* not recordable, *ND* not done)

Study	Initial					Final				
	No. of patients	No. of sides	NR (sides)	Prolonged (sides)	Normal (sides)	No. of patients	No. of sides	NR (sides)	Prolonged (sides)	Normal (sides)
<i>CMCT-ADM</i>	33	66	5	12	49	24	48	0	3	45
<i>CMCT-TA</i>	39	78	47	19	12	23	46	20	6	20
SEP median	33	66	5	4	57	22	44	0	0	44
SEP tibial	39	78	48	7	23	22	44	21	5	18

Table 2 Motor (MEPs) and somatosensory (SEPS) evoked potential changes (ms) in patients with acute transverse myelitis (NR not recordable)

Patient no.		CMCT-ADM		CMCT-TA		Median SEP N9-N20		Tibial SEP N21-p40	
		MEPs	SEPs	MEPs	SEPs	MEPs	SEPs	MEPs	SEPs
2 < ?1 >	Initial	5.2	7.0	33.6	25.2	10.2	10.2	18.0	15.0
	Final	5.0	7.1	25.2	14.4	10.2	10.2	18.0	15.0
3 < ?1 >	Initial	NR	NR	NR	NR	8.8	8.8	NR	NR
	Final	7.6	7.6	NR	NR	8.4	8.4	NR	NR
5 < ?1 >	Initial	10.4	NR	NR	NR	9.6	9.6	NR	NR
	Final	5.2	10.4	NR	NR	9.6	9.4	NR	NR
9 < ?1 >	Initial	10.0	9.6	45.6	43.6	8.4	9.2	28.0	NR
	Final	4.2	6.8	18.0	20.0	8.4	8.4	26.0	NR
10 < ?1 >	Initial	7.2	7.2	19.2	18.8	12.0	9.6	23.0	32.0
	Final	8.0	6.9	18.8	16.4	10.0	9.6	25.0	24.0
13 < ?1 >	Initial	6.8	4.4	NR	NR	8.4	8.0	NR	NR
	Final	6.6	4.2	16.4	16.0	8.4	8.2	26.0	28.0
17 < ?1 >	Initial	5.3	3.4	NR	NR	8.6	8.6	NR	NR
	Final	5.2	3.4	13.6	12.4	8.4	8.4	24.8	20.4
22 < ?1 >	Initial	4.8	6.5	NR	NR	7.2	8.4	NR	NR
	Final	5.2	5.5	NR	13.2	8.0	8.4	NR	NR
23 < ?1 >	Initial	5.2	5.2	36.4	36.0	15.6	15.8	NR	NR
	Final	5.4	5.4	25.0	16.0	8.0	8.0	25.6	18.8
24 < ?1 >	Initial	4.8	6.8	NR	NR	9.2	8.8	24.0	31.2
	Final	4.8	6.4	14.0	17.2	9.0	9.0	19.6	19.8
25 < ?1 >	Initial	4.4	3.6	NR	NR	8.8	8.4	17.6	18.2
	Final	4.4	3.8	13.6	NR	8.8	8.4	15.6	15.6
26 < ?1 >	Initial	6.0	4.8	14.4	NR	7.6	7.2	NR	NR
	Final	5.6	4.8	12.8	14.8	7.6	7.2	NR	NR
28 < ?1 >	Initial	8.0	8.4	NR	NR	10.4	10.0	NR	NR
	Final	5.6	4.8	NR	NR	10.4	10.4	NR	NR
29 < ?1 >	Initial	10.4	10.4	18.0	16.4	NR	NR	NR	19.2
	Final	6.4	7.2	12.4	17.6	10.0	10.0	21.4	22.4
30 < ?1 >	Initial	4.8	6.0	32.0	24.0	7.6	8.0	21.4	22.0
	Final	6.4	5.6	9.6	8.8	8.8	9.2	18.8	18.8
31 < ?1 >	Initial	5.2	9.2	12.0	NR	8.4	8.8	16.0	19.0
	Final	3.6	5.6	13.2	18.8	8.4	8.8	16.2	18.8
39 < ?1 >	Initial	11.6	5.6	NR	NR	7.6	8.0	NR	NR
	Final	4.8	6.8	NR	NR	7.6	8.0	NR	NR
Control value		5.1±1.2	5.1±1.2	12.1±1.6	12.1±1.6	8.3±1.2	8.3±1.2	20.1±2.8	20.1±2.8
Cut-off point		8.1	8.1	16.1	16.1	11.3	11.3	27.1	27.1

Discussion

Neurophysiological studies carried out in patients with ATM revealed that CMCT-TA was the most commonly involved (90%) followed by tibial SEPs (77%). The upper limbs were involved in a minority of patients, but in them MEPs were also more commonly affected (30%) than SEP (15%). These results are consistent with the more frequent involvement of thoracic spinal cord in ATM than the cervical, which is affected in 10% patients only [3]. In an earlier study we reported cervical cord involvement in seven

of ten patients on the basis of clinical, MRI and neurophysiological findings [10]. In the present study some evidence of cervical spinal cord involvement was found in 56% patients.

In our study diverse evoked potential changes were found and included unrecordable, prolongation of central motor or sensory conduction time and normal evoked potentials. These findings were associated with varying severity of EMG evidence of denervation which suggested the involvement of anterior horn cells. Unrecordable, prolonged or normal evoked potentials reflect the decreasing severity of spinal cord involvement. Unrecordable motor

and sensory evoked potentials may be due to necrosis, oedema and severe demyelination resulting in conduction block. The prolongation of central conduction time may be due to dispersion and/or demyelination. The normal evoked potentials may be due to milder involvement or sparing of fast-conducting motor or sensory pathways [8, 11, 12]. MEPs and SEPs had a good correlation with respective motor or sensory findings.

The follow-up study of evoked potentials revealed that the lower limb findings were rather stable. Those in upper limb revealed more frequent changes. The higher frequency of improvement in evoked potential findings in the upper than the lower limbs may be due to less involvement of the cervical spinal cord. In ATM patients histopathological studies have revealed that the necrotic changes in the spinal cord are prominent in thoracic region. The histopathological changes, however, exceeded 12–16 segments above the sensory level and revealed more of oedema and demyelination [4]. The more frequent improvement in upper limb evoked potential findings including CMCT-ADM and median SEP at 3-month follow-up may be due to reduction in oedema and remyelination in our patients. In 20 of our patients there were EMG evidence of denervation suggesting anterior horn cell involvement. EMG evidence of denervation has been reported to be associated with poor prognosis of ATM [7]. The involvement of anterior horn cell may only suggest more extensive and severe damage of spinal cord and hence a poor prognosis.

Patients with multiple sclerosis may also present with ATM; however, their clinical, radiological and neurophysiological findings are distinctive. None of our patient had clinical evidence of multiple sclerosis. T2-weighted MRI in multiple sclerosis patients reveals hyperintensity restricted to two segments, or spinal MRI may even be normal [2]. In ATM, on the other hand, the signal changes are extensive. In our study only two patients had MRI signal changes restricted to two segments, and three had normal MRI. In all these patients there was evidence of fibrillation in lower limb muscles, which is not a feature of multiple sclerosis. MRI study revealed cervical cord involvement in

20 of 31 patients, but upper limb weakness was noted in only 8 patients. MRI shows pathological abnormalities that may not have clinical or pathological consequences. MRI involvement above the sensory level has been reported in ATM by earlier authors [1, 10]. Histopathological changes in ATM include oedema, demyelination and necrosis of spinal cord [4]. In our patients MRI revealed hyperintense signal changes on T2-weighted images that was hypointense on T1-weighted images in all except one which may be consistent with oedema, demyelination or necrosis. In only one patient were MRI changes suggestive of haemorrhagic changes. It is not possible to establish a correlation between MRI changes and the reported histopathological findings, which obviously include more severe cases.

Outcome among our ATM patients was correlated with initial MEP and SEP changes and EMG evidence of denervation. The evoked potential changes may be more useful than EMG as these reveal abnormalities early in the course of illness whereas the EMG changes appear only after 10–15 days of illness. Another study on the prognostic predictors in ATM reports that the severity of weakness and EMG evidence of denervation predicted the outcome in 90.3% patients; addition of other neurophysiological parameters did not improve the predictive value [6]. A Japanese study of evoked potentials in encephalitis, which is actually an encephalomyelitis, found MEP to have an important role in predicting the outcome [9]. Patients with ATM may show improvement beyond 3 months. This may be due to reorganisation of sensory motor pathways. In our study, however, only one patient showed further improvement at 6 months compared to that at 3 months. The extent of MRI changes in our study, however, was not correlated with outcome. The necrotic changes may suggest a poor outcome and oedema may not. The differentiation between necrosis and oedema may not be easy in MRI.

We conclude from these findings that neurophysiological evaluation helps in objectively documenting the motor and sensory deficit and predicting the outcome of ATM.

Acknowledgements We thank Mr. Rakesh Kumar Nigam for secretarial help.

References

1. Barakos JA, Mark AS, Dillon WP, Norman D (1990) MR imaging of acute transverse myelitis and AIDS myelopathy. *J Comput Assist Tomogr* 14:45–50
2. Choi KH, Lee KS, Chung SO, park JM, Kim YJ, KIM HS, Shinn KS (1996) Idiopathic transverse myelitis: MR characteristic. *AJNR Am J Neuroradiol* 17:1151–1160
3. Dawson DM, Potts F (1991) Acute non-traumatic myelopathies. In: Woolsey RM, Yound RR (eds) *Neurologic clinics. Disorders of the spinal cord*, Saunders, Philadelphia, pp 551–603
4. Hoffman HL (1955) Acute necrotic myelopathy. *Brain* 78:377–393
5. Jeffery DR, Mandler RN, Davis L (1993) Transverse myelitis – retrospective analysis of 33 cases with differentiation of cases associated with multiple sclerosis and parainfectious events. *Arch Neurol* 50:532–535
6. Kalita J, Misra UK, Mandal SK (1998) Prognostic predictors of acute transverse myelitis? *Acta Neurol Scand* 98:60–63
7. Misra UK, Kalita J (1998) Can electromyography predict the prognosis of transverse myelitis? *J Neurol* 245:741–744
8. Misra UK, Sharma VP (1994) Central and peripheral conduction in neuro-lathyrism. *J Neurol Neurosurg Psychiatry* 57:572–577
9. Misra UK, Kalita J (1999) Motor and somatosensory evoked potentials in Japanese encephalitis. *Neurol Infect Epidemiol* (in press)

-
- 10 Misra UK, Kalita J, Kumar S (1996) A clinical, MRI and neurophysiological study of acute transverse myelitis. *J Neurol Sci* 138:150–156
 11. Ropper AH, Mielt T, Chiappa KH (1982) Absence of evoked potential abnormalities in acute transverse myelopathy *Neurology* 32:80–82
 12. Thompson PD, Dick JPR, Asselmann P, et al (1987) Examination of motor functions in lesions of the spinal cord by stimulation of the motor cortex. *Ann Neurol* 21:389–396