

See discussions, stats, and author profiles for this publication at: <https://www.researchgate.net/publication/273712709>

# Arteriovenous Fistula: An Unusual Complication during Transarterial Chemoembolization

Article in *Euroasian Journal of Hepato-Gastroenterology* · January 2011

DOI: 10.5005/jgp-journals-10018-1007

CITATIONS

0

READS

101

7 authors, including:



**Devasenathipathy Kandasamy**

All India Institute of Medical Sciences

186 PUBLICATIONS 686 CITATIONS

[SEE PROFILE](#)



**Ramesh Kumar**

Bannari Amman Institute of Technology

69 PUBLICATIONS 1,161 CITATIONS

[SEE PROFILE](#)



**Shashi Paul**

All India Institute of Medical Sciences

74 PUBLICATIONS 965 CITATIONS

[SEE PROFILE](#)



**Subrat Acharya**

All India Institute of Medical Sciences

384 PUBLICATIONS 9,402 CITATIONS

[SEE PROFILE](#)

Some of the authors of this publication are also working on these related projects:



Immunological and parasitological aspects of visceral leishmaniasis [View project](#)



Non-invasive Imaging-based Chemotherapeutic Response Evaluation in Bone Tumor using multi-parametric MRI [View project](#)

# Arterio biliary Fistula: An Unusual Complication during Transarterial Chemoembolization

<sup>1</sup>YC Manjunatha, <sup>1</sup>Shivanand Gamanagatti, <sup>1</sup>Devasenathipathy Kandasamy, <sup>2</sup>Ramesh Kumar  
<sup>2</sup>Saurab Kedia, <sup>1</sup>Shashi Bala Paul, <sup>2</sup>Subrat Kumar Acharya

<sup>1</sup>Department of Radiodiagnosis, All India Institute of Medical Sciences, New Delhi, India

<sup>2</sup>Department of Gastroenterology, All India Institute of Medical Sciences, New Delhi, India

**Correspondence:** Shashi Bala Paul, Scientist, Department of Radiodiagnosis, All India Institute of Medical Sciences, Ansari Nagar, New Delhi-110029, India, Phone: 91-11-26594889, Fax: 91-11-26588663, e-mail: shashi.aiims@gmail.com

## ABSTRACT

Arterio biliary fistula during transarterial chemoembolization (TACE) is very rare. However, it is vital to manage the arterio biliary fistula to prevent the life-threatening complications of hemobilia. This study deals with an arterio biliary fistula identified during the procedure of TACE undertaken for the treatment of hepatocellular carcinoma (HCC) and managed successfully by embolizing the proximal segmental hepatic artery using microcoil.

**Abbreviation:** TACE—Transarterial chemoembolization; HCC—Hepatocellular carcinoma; ALT—Alanine aminotransferase; HBsAg—Hepatitis B surface antigen; USG—Ultrasonography; FNAC—Fine needle aspiration cytology; HBV—Hepatitis B virus; CBD—Common bile duct.

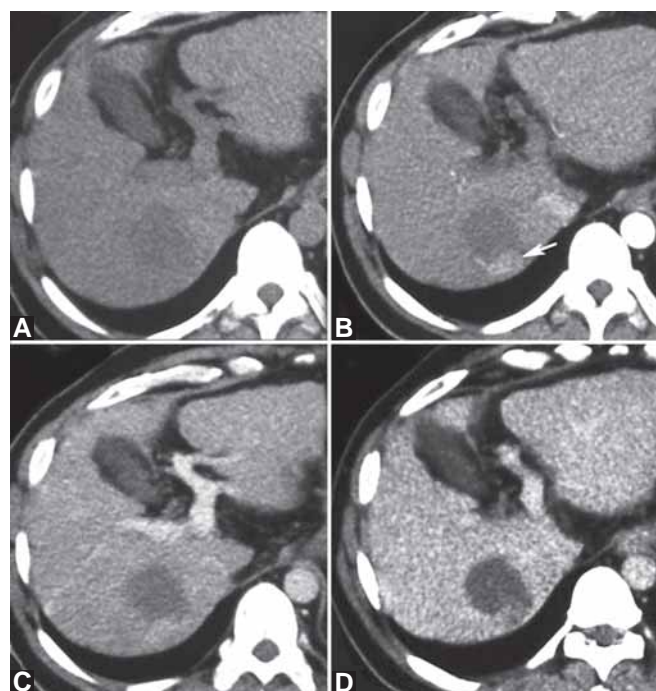
**Keywords:** Transarterial chemoembolization (TACE), Arterio biliary fistula, Hemobilia, Hepatocellular carcinoma, Computed tomography.

## CASE REPORT

A 46-year-old male, a known case of hepatitis B related liver cirrhosis since February 2008, was referred to our hospital with the suspicion of a mass in the liver. He was asymptomatic at presentation and his general physical as well as systemic examinations were unremarkable. He had past history of multiple bouts of hematemesis and had undergone periodical endoscopic variceal ligation. Investigations revealed the following: Hemoglobin—11.9 gm/dl, leukocyte count—6,400/mm<sup>3</sup>, platelet count—64,000/mm<sup>3</sup>, prothrombin time—14.3 seconds (control 13 seconds), total bilirubin—1.2 mg/dl; direct bilirubin—0.4 mg/dl. Aspartate aminotransferase (AST)—111 IU/L, alanine aminotransferase (ALT)—83 IU/L, alkaline phosphatase—168 IU/L, total protein/albumin—8.2/3.9 gm/dl and serum creatinine—0.8 mg/dl. The  $\alpha$ -fetoprotein level was within normal upper limit (9.3 ng/ml). He was positive for hepatitis B virus surface antigen (HBsAg), HBeAg was negative and the HBV DNA load was 5 log 10 copies/ml.

Ultrasonography (USG) of upper abdomen showed features of liver cirrhosis with dilated portal vein, splenomegaly, ascites, multiple para esophageal collaterals and a well-defined hypoechoic focal lesion in segment VII of liver measuring approximately 1.9 × 1.2 cm. Multiphase CT scan of liver showed a well-defined hypodense lesion in segment VII on noncontrast images. Posterior part of the lesion showed focal enhancement in arterial phase with

persistent enhancement in venous phase and washout in the enhancing part on the delayed images (Figs 1A to D). However, the majority of the anterior part of the lesion did

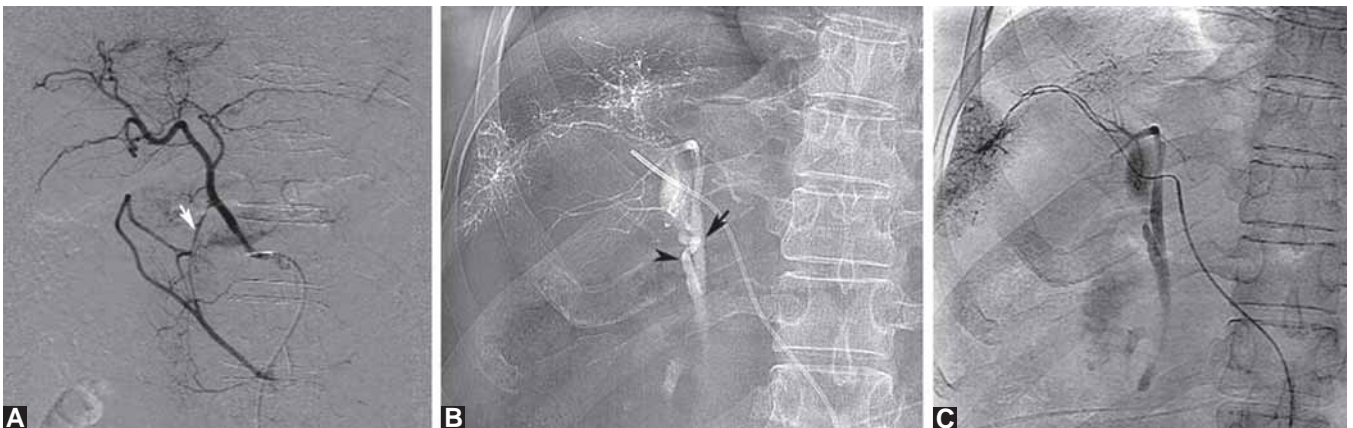


**Figs 1A to D:** Multiphase CT study, noncontrast image (A) showing a focal hypodense lesion in segment VII of liver. Arterial phase image (B) shows enhancing posterior aspect of the hypodense lesion (arrow), which is showing enhancement equal to rest of the liver on the venous phase image (C) and delayed image (D) showing washout of contrast in the enhancing area. FNAC confirmed HCC

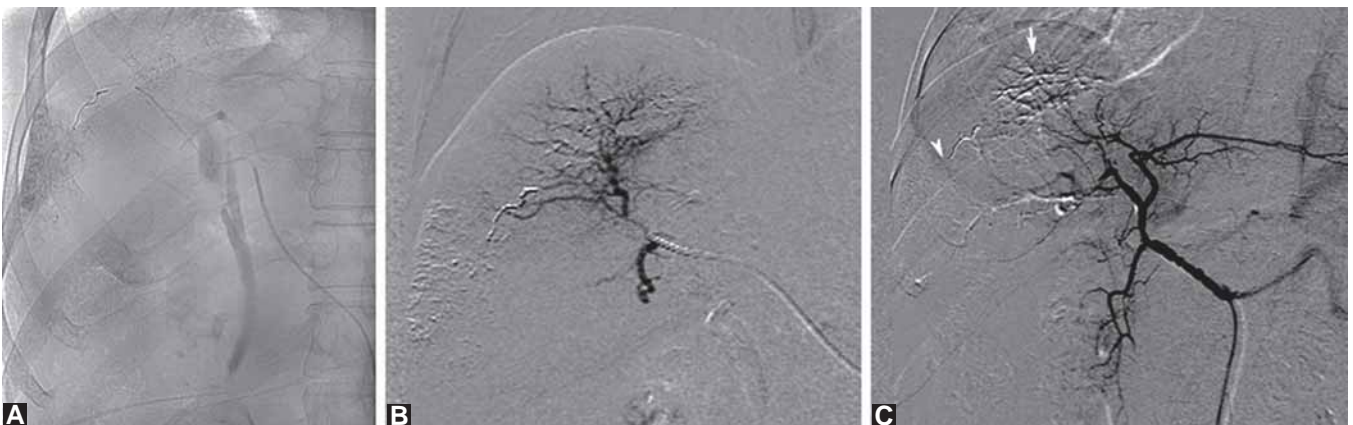
not show enhancement on any phase of contrast CT. As the imaging findings were inconclusive, ultrasound-guided fine needle aspiration cytology (FNAC) was done with 22G spinal needle for confirmation of diagnosis. FNAC done for first time was inconclusive and repeat FNAC suggested hepatocellular carcinoma (HCC). Final diagnosis of hepatitis B virus (HBV) related Child-A liver cirrhosis with portal hypertension and HCC was made.

Transarterial chemoembolization (TACE) was considered as the treatment option for this patient. The procedure of TACE was planned through transfemoral approach. A selective arteriogram of common hepatic artery was done with 5F catheter, which showed tumor supplied by the segmental artery and there was no evidence of arterio-biliary fistula (Fig. 2A). The catheter was advanced to the right hepatic artery for the injection of chemotherapeutic drug mixture. When the injection of chemotherapeutic drug mixture (Epirubicin 60 mg mixed in 10 ml of Lipiodol) was started, the opacification of common bile duct (CBD) with lipiodol (Fig. 2B) was noted. Immediately, injection of the

chemotherapeutic drug mixture was stopped. The target segmental artery was selectively catheterized with a 3F microcatheter and an angiogram was obtained. An arterio-biliary communication with opacification of adjacent biliary radicals, CBD and cystic duct (Fig. 2C) was identified. The segmental hepatic artery was then embolized with 18-3-3 platinum microcoils (Cook, Bloomington, USA) (Fig. 3A). On subsequent arteriogram, no opacification of biliary radical or CBD was seen (Fig. 3B) depicting complete embolization. Subsequently the chemotherapeutic drug was injected selectively into the segment VII branch and the procedure was completed with good lipiodol opacification of tumor bed (Fig. 3C). Patient tolerated the procedure well and the postprocedure period was uneventful. One month follow-up multiphase CT scan showed lipiodol opacification surrounding the focal lesion and in the posterior aspect of the lesion [portion enhancing on previous CT (Figs 4A to C)]. There was no arterial enhancing lesion or component in the follow-up CT scan.

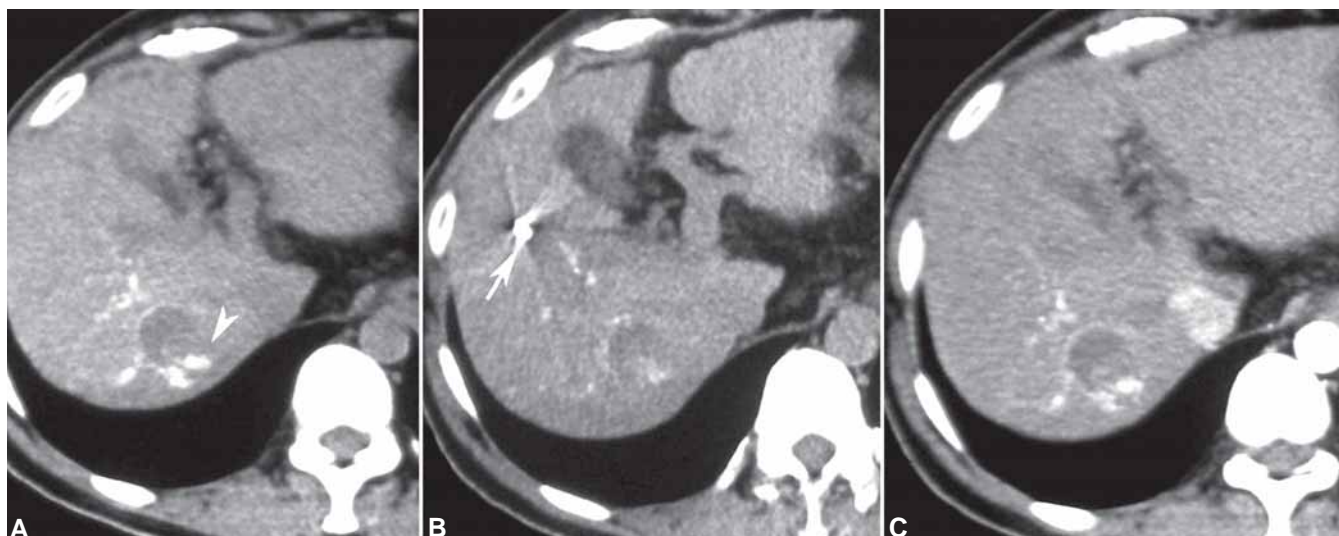


**Figs 2A to C:** (A) Selective arteriogram of common hepatic artery shows normal right and left hepatic arteries and note also the filling of contrast in gastroduodenal artery (arrow). (B) Opacification of common bile duct (arrow) and cystic duct (arrow head) with lipiodol is seen when injecting chemotherapeutic drug into right hepatic artery (segment VII and VIII branches). (C) Super selective arteriogram of the target artery with 3F microcatheter showing the arterio-biliary fistula with opacification of biliary system



**Figs 3A to C:** (A) Single shot image showing microcoil deployed in the target hepatic artery. (B) Arteriogram showing complete hemostasis at the arterio-biliary fistula without opacification of biliary system. (C) Arteriogram after coil and chemoembolization showing nonopacification of fistula (arrow head) and tumor bed vessels (arrow) in right lobe





**Figs 4A to C:** One month follow-up multiphase CT noncontrast images (A and B) showing lipiodol deposition in the periphery and within the enhancing component of the lesion (arrow head) in the previous arterial phase image (Fig. 1B). (C) Note the embolization coil *in situ* (arrow). No enhancing component seen on arterial phase image

## DISCUSSION

Arterio-biliary fistula is rare and results in potentially life-threatening condition called hemobilia. The most common cause for hemobilia is liver biopsy, however, it is attributed to less than 1% of these cases.<sup>1</sup> Other causes include biliary lithiasis and infection, trauma, malignancy, arterioportal fistula, hepatobiliary surgery, pseudoaneurysm of hepatic artery, various hepatic interventions like percutaneous transhepatic biliary drainage, percutaneous cholangiography, endobiliary prosthesis placement and abscess drainage.<sup>2</sup> There has been one case report of asymptomatic arterio-biliary fistula after repeated transarterial chemoembolization for metastatic liver tumor.<sup>3</sup>

The classic signs and symptoms include a triad of colicky pain in right upper quadrant, jaundice and upper gastrointestinal hemorrhage (hematemesis and/or melena).<sup>2</sup> In our case, the patient had no signs and symptoms of hemobilia and the arterio-biliary fistula was detected during therapeutic procedure. He had history of fine needle aspiration twice, and probably due to this iatrogenic trauma, the arterio-biliary barrier was given way resulting in fistulous communication due to increased force/velocity of blood and contrast flow during selective intra-arterial injection of contrast through the hepatic artery. Early recognition and management of arterio-biliary fistula is extremely important to prevent life-threatening complications. Therefore, on detection during the procedure, the embolization was successfully achieved followed by introduction of chemotherapeutic drugs.

The treatment options include surgery and percutaneous transarterial embolization of arterio-biliary fistula.

Percutaneous transcatheter approach is safe, reliable, minimally invasive and preferred due to its significant reduction in morbidity and mortality as compared to surgery. Once the fistulous site is identified with selective arteriographies of celiac, superior mesenteric and common hepatic arteries, 5 to 6F catheter is inserted into the targeted branch and embolization is performed. If the target artery is comparatively small, embolization is performed with 3F microcatheter passed through a 5F catheter placed in the main trunk, and after advancing the microcatheter with guide wire into the corresponding target hepatic artery branch temporary [Gelfoam, (Pharmacia & Upjohn Co. Kalamazoo, MI, USA)] and permanent embolizing material [Microcoils, (Cook, Bloomington, USA)], polyvinyl alcohol (PVA), alone or in combination have been used. After embolization, check arteriogram should be performed to confirm absolute hemostasis.<sup>4,5</sup> In our case, the target artery diameter was small for 5F catheter, and hence we used 3F microcatheter coaxially and embolized with Cook 18-3-3 microcoil alone. Absolute hemostasis was achieved subsequently.

Majority of these fistulas treated by percutaneous transarterial route reported in literature were due to pseudoaneurysms of hepatic or cystic artery, which were effectively treated with gelfoam and microcoils. If the cause for hemobilia is not identified by selective arteriographies or there is diffuse hepatic artery branch bleeding, such cases are embolized with gelfoam or PVA particles.<sup>4</sup> Authors have reported massive hemobilia due to right hepatic artery pseudoaneurysm, which was successfully treated with balloon expandable covered stent deployed at the site of fistula.<sup>2</sup>

To conclude, arteriobiliary fistula during TACE is rare. Familiarization of this entity, identification of the fistulous communication during the procedure and appropriate management is vital to prevent the life-threatening complication of hemobilia.

## REFERENCES

1. Edden Y, St Hilaire H, Benkov K, Harris MT. Percutaneous liver biopsy complicated by hemobilia-associated acute cholecystitis. *World J Gastroenterol* 2006;12:4435-36.
2. Demyttenaere SV, Hassanain M, Halwani Y, Valenti D, Barkun JS. Massive hemobilia. *Can J Surg* 2009;52: E109-10.
3. Chen JH, Ho YJ, Shen WC. Asymptomatic arteriobiliary fistula after transarterial chemoembolization of metastatic liver tumors. *Hepatogastroenterology* 2001;48:842-43.
4. Xu ZB, Zhou XY, Peng ZY, Xu SL, Ruan LX. Evaluation of selective hepatic angiography and embolization in patients with massive hemobilia. *Hepatobiliary Pancreat Dis Int* 2005;4: 254-58.
5. Srivastava DN, Sharma S, Pal S, et al. Transcatheter arterial embolization in the management of hemobilia. *Abdom Imaging* 2006;31:439-48.