

ROLE OF SPLEEN SCANNING IN PLANNING THE TREATMENT AND ASSESSMENT OF SPLENIC RESPONSE IN BLOOD DYSCRASIAS*

By S. M. SHARMA, M.B.B.S., D.M.R.T.; M. C. PATEL, B.Sc.;
P. RAMANATHAN, B.Sc.; and R. D. GANATRA, M.B.B.S., F.C.P.S., M.Sc.

BOMBAY, INDIA

THE property of the spleen to remove partially damaged red blood cells from the blood stream has been utilized by a number of investigators to obtain spleen scans. Johnson *et al.*⁶ employed sensitized red blood cells for scanning the spleen. Harris *et al.*⁵ later demonstrated sequestration of heat-treated autologous red blood cells in the spleen. Wagner and his colleagues¹¹ obtained spleen scans of some of their patients by using N-ethyl maleimide (NEM) to damage the red blood cells. However, they found that of all the techniques, the heat treatment method was most satisfactory. More recently, an easier and less cumbersome technique for obtaining spleen scans has been suggested using 1-bromo mercury 2-hydroxypropane (BMHP) labeled with radioactive mercury.¹²

A number of workers have demonstrated the usefulness of spleen scans in diagnosing a variety of diseases.^{2,3,4,8,11} They found spleen scans to be helpful in the detection and quantitation of splenomegaly, in the differential diagnosis of obscure abdominal masses, and in the delineation of space-occupying lesions of the spleen. We have also found scanning of the spleen to be of special assistance in locating the best site for external irradiation of the spleen and in assessing the response of the spleen to therapy in some of our cases of chronic myeloid leukemia, Hodgkin's disease and polycythemia vera.

MATERIAL AND METHODS

Spleen scanning was performed on a series of 28 patients. The series included 7

cases of polycythemia vera, 1 case of secondary polycythemia, 8 cases of acute and chronic myeloid and lymphatic leukemia, and 1 case of Hodgkin's disease. The remaining 11 patients had a variety of disease conditions, *i.e.* hemolytic anemia, obscure abdominal masses, generalized lymphadenopathy, hydatid cyst of the liver and bone metastasis from an unknown primary lesion.

TECHNIQUE OF LABELING AND HEAT TREATMENT OF RED BLOOD CELLS

A sterile syringe was used to withdraw 15–20 ml. of the patient's blood. The blood was transferred into a screw cap vial containing 4 ml. of modified ACD solution to which 200–300 μc of Cr^{51} in the form of high specific activity sodium chromate (110 $\mu\text{c}/\mu\text{g.}$) was added. The mixture was incubated at 37° C. for 20 minutes. About 100 mg. of ascorbic acid was then added to stop further labeling of red blood cells. The labeled blood was again incubated at 49° \pm 1° C. in a shaking water bath for 60 minutes.

After a brief cooling the blood was re-injected into the patient.

TECHNIQUE OF SPLEEN SCANNING

Spleen scanning was performed 2 to 4 hours after the injection of heat-treated Cr^{51} labeled red blood cells. An isotope scanner having a 3 inch \times 3 inch thallium activated sodium iodide crystal fitted with a 19 hole honeycomb collimator was used. All the patients were scanned in the prone position. The scattered radiation from surrounding tissues was selectively eliminated by using a γ -ray spectrometer ad-

* From the Radiation Medicine Centre, Medical Division, Atomic Energy Establishment Trombay, Tata Memorial Hospital, Parel, Bombay-12, India.

justed around the photopeak of Cr^{51} with a window width of 10 volts. The scanning speed employed was 24 cm. per minute. The dot factor for dot scans and the percentage cut-off for photoscans were adjusted according to the count rates over the spleen of individual patients. In a

number of patients, ordinary photographic printing paper was used instead of the conventional single emulsion photoscanning film. The use of readily available and inexpensive photographic printing paper for photoscanning has been described previously.⁹

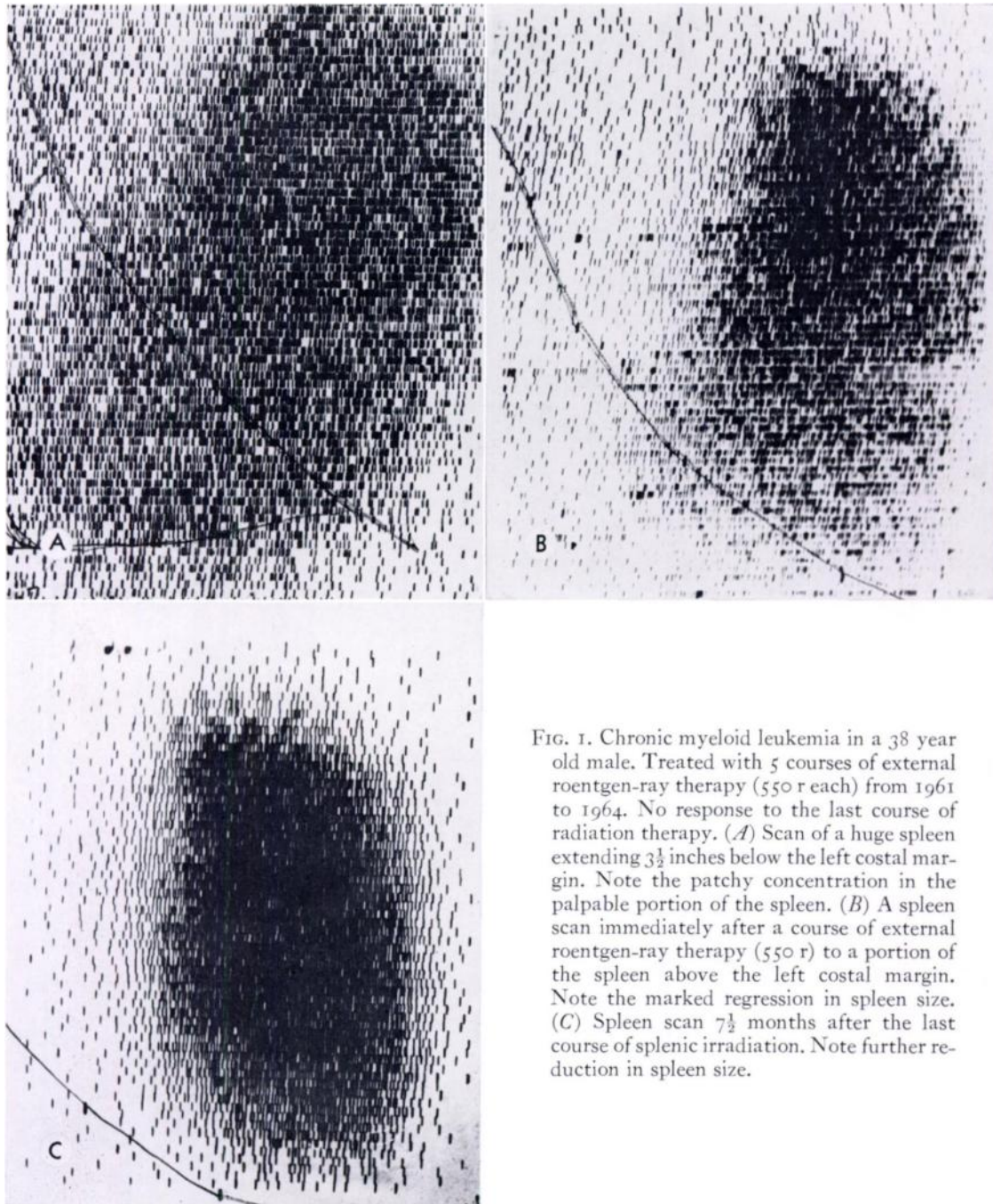


FIG. 1. Chronic myeloid leukemia in a 38 year old male. Treated with 5 courses of external roentgen-ray therapy (550 r each) from 1961 to 1964. No response to the last course of radiation therapy. (A) Scan of a huge spleen extending $3\frac{1}{2}$ inches below the left costal margin. Note the patchy concentration in the palpable portion of the spleen. (B) A spleen scan immediately after a course of external roentgen-ray therapy (550 r) to a portion of the spleen above the left costal margin. Note the marked regression in spleen size. (C) Spleen scan $7\frac{1}{2}$ months after the last course of splenic irradiation. Note further reduction in spleen size.

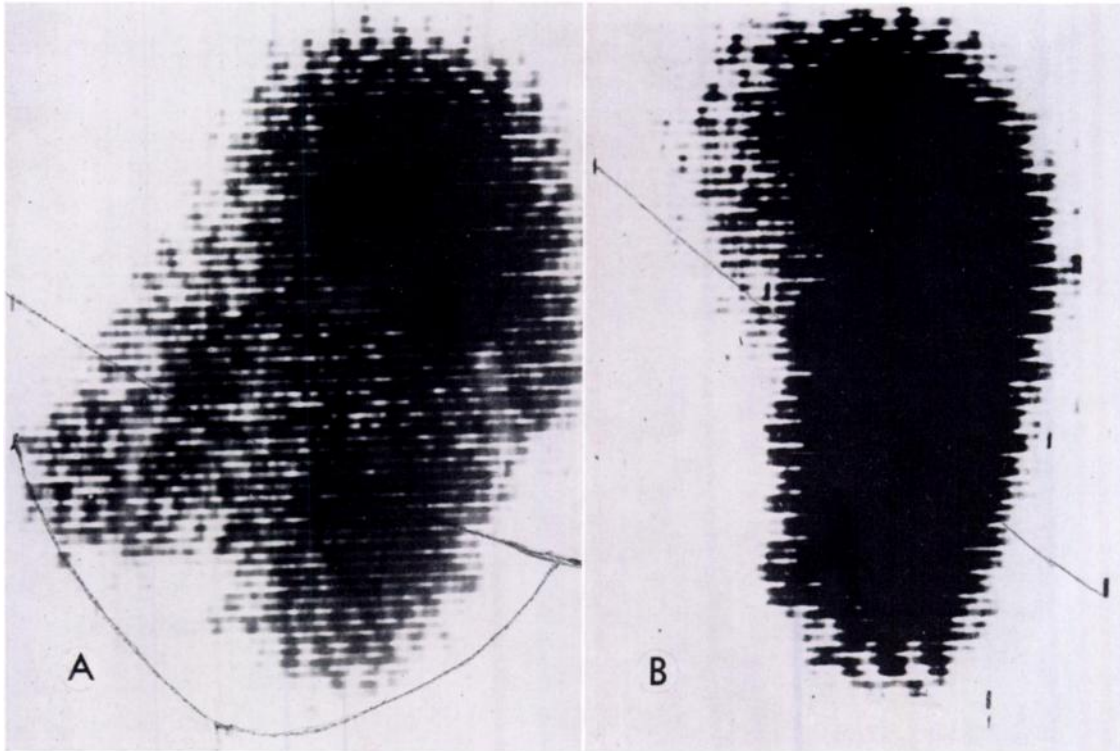


FIG. 2. Hodgkin's disease in a 52 year old male. Previously treated with external roentgen-ray therapy to neck and axillary lymph nodes. (A) Scan of an enlarged spleen extending 2 inches below the left costal margin. A well defined comparatively "cold" mass is seen in the region of the hilus of the spleen. (B) Repeat scan immediately after a 12 day course of intravenous endoxan. A considerable reduction in the bulk of the spleen is visible. The comparatively "cold" mass in the region of the hilus has completely disappeared.

RESULTS

The authors have found spleen scanning of considerable aid in the follow-up of patients with various hematologic disorders and in the evaluation of their response to therapy. Four case histories are presented.

CASE I. A 38 year old male was first seen at this hospital 4 years ago with an enlarged spleen, loss of weight, loss of appetite and anemia. No lymphadenopathy was detected. Bone marrow and peripheral blood smear examinations revealed chronic myeloid leukemia. From 1961 until December, 1964 the disease was kept under control by repeated small doses of roentgen irradiation of the spleen (5 courses of 550 r each). The last course of splenic irradiation did not produce a satisfactory remission and it was thought that the disease was becoming resistant to roentgen rays. The scan showed a huge spleen extending $3\frac{1}{2}$ inches below

the left costal margin (Fig. 1A). Compared to a uniform concentration in the upper $\frac{2}{3}$ of the spleen, the lower $\frac{1}{3}$ showed a patchy concentration. On the assumption that the patchy concentration in the lower $\frac{1}{3}$ of the spleen was due to radiation fibrosis another course of roentgen-ray therapy was given to a portion of the spleen above the left costal margin. A total of 550 r was delivered. Figure 1B shows the spleen scan of the patient immediately after the radiation therapy. The scan reveals a definite reduction in the size of the spleen. No extension of the spleen below the left costal margin is demonstrated. The red blood cell count dropped. A spleen scan obtained $7\frac{1}{2}$ months later (Fig. 1C) showed further reduction in the size of the spleen. The disease was well under control during this period without any specific treatment.

CASE II. Three years prior to the present examination a diagnosis of Hodgkin's disease had

been made from an inguinal lymph node biopsy in this 52 year old male. He had been previously treated with roentgen-ray therapy of the neck and inguinal lymph nodes. At the present examination he had hard and matted lymph nodes in both axillary and inguinal regions. The spleen and liver were enlarged. The scan demonstrated a large spleen extending 2 inches below the left costal margin (Fig. 2*A*). A well-defined comparatively "cold" mass was seen in the region of the hilus and along the medial border of the lower pole of the spleen. A scan of the patient 12 days after the initial scan is shown in Figure 2*B*. The patient received 200 mg. of endoxan by intravenous route daily during the interim period (for a total dose of 2,200 mg.). A considerable reduction in the size of the spleen ensued although the over-all length of the spleen in the 2 scans remained almost the same. The large "cold" mass noted in the previous scans has completely disappeared.

CASE III. A 68 year old female was referred to us with a history of 2 attacks of coronary thrombosis. Clinical examination and laboratory investigations indicated polycythemia vera. The spleen was not palpable. The scan showed an enlarged comma-shaped spleen which extended an inch below the left costal margin, along with a longer projection along the lateral abdominal wall (Fig. 3*A*). A repeat scan (Fig. 3*B*) obtained when the polycythemia was under control after 7 mc of oral radioactive phosphorus revealed a marked reduction in the size of the spleen. No extension below the left costal margin was noted.

CASE IV. A 66 year old male patient presented with a history of hypertension. He had multiple ecchymotic pathes over both extremities. Evidence of deep seated thrombosis in both legs was also present. The liver and spleen were not palpable. Laboratory investigations suggested polycythemia vera. The scan showed a very bulky spleen even though it did not extend be-

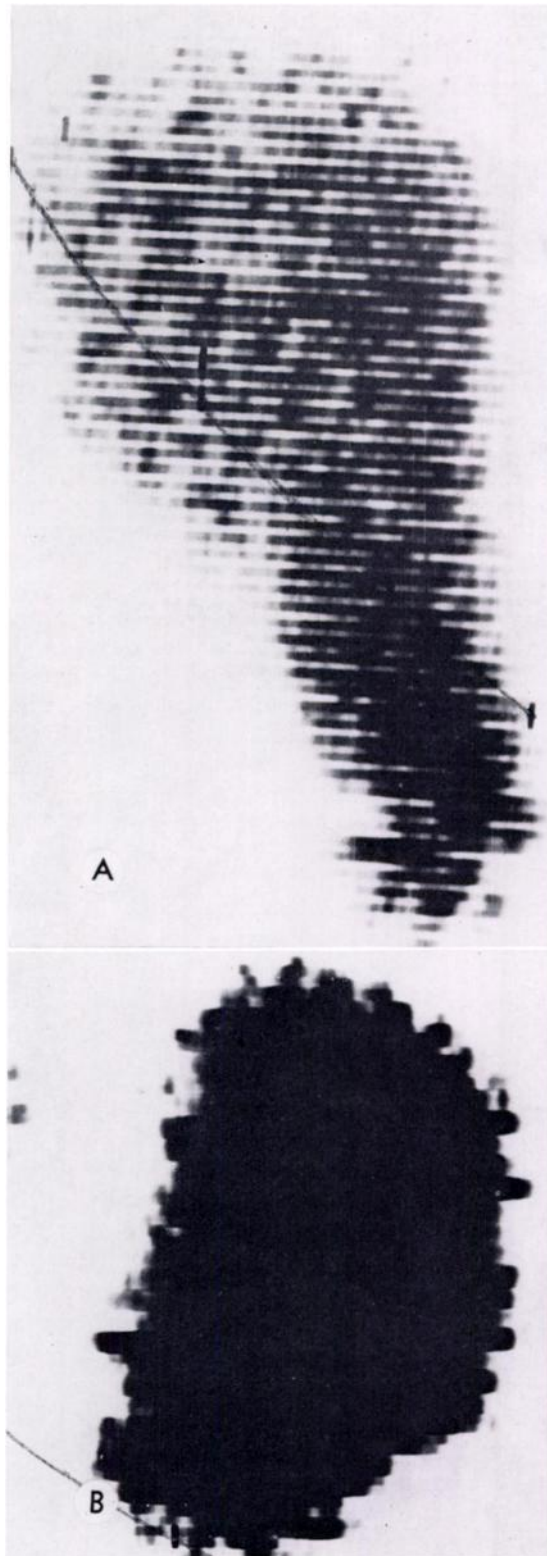


FIG. 3. Polycythemia vera in a 68 year old female. The spleen was not palpable. (A) Scan shows an enlarged spleen. A narrow projection along the lateral abdominal wall is noted. (B) Repeat scan after an oral 7 mc dose of radiophosphorus. The disease is under control and there is a marked reduction in the spleen size.

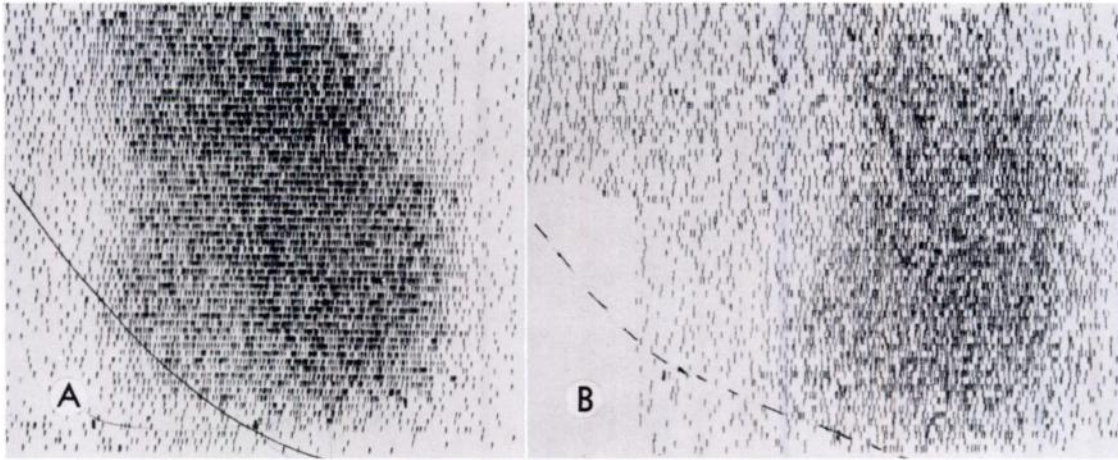


FIG. 4. Polycythemia vera in a 66 year old male. The spleen was not palpable. (A) Scan showing a bulky spleen even though no extension below the left costal margin is seen. (B) Repeat scan after an oral 7 mc dose of radiophosphorus. With the disease under control there is a considerable reduction in the bulk of the spleen.

low the left costal margin (Fig. 4A). A repeat scan obtained 1 year after the first scan is shown in Figure 4B. During this period he had received an oral dose of 7 mc of radioactive phosphorus. The scan reveals a regression in the size of the spleen of more than 1 inch in length and its bulk is also considerably reduced.

DISCUSSION

It is generally recognized that all forms of treatment of leukemia and other allied blood dyscrasias aim at prolonging the life span of the patient with minimum morbidity.⁷ It is, therefore, desirable that maximum advantage should be taken of either radiation therapy or chemotherapy as a preferred mode of treatment. The patient with chronic myeloid leukemia (Case 1; Fig. 1, A-C) demonstrated the usefulness of spleen scanning in obtaining the maximum benefit from splenic roentgen irradiation. Repeated roentgen-ray treatments to the same area of the spleen during a period of 4 years probably resulted in radiation-induced interstitial fibrosis in the lower $\frac{1}{3}$ of the spleen. The last course of splenic irradiation at the same site, just before spleen scanning, therefore did not produce a remission. The spleen scan proved helpful in detecting an area of the spleen with good concentration; another

dose of 550 r over this area produced a remission lasting for 7½ months.

The Hodgkin's mass in the region of the hilus of the spleen (Fig. 2A) disappeared after 12 days of intravenous endoxan therapy (Fig. 2B). The post-therapy scan in this patient has provided definite evidence of regression of the lesion in the spleen.

An interesting feature of the 2 patients with polycythemia vera was that even though there was no clinical evidence of a palpable spleen, the spleen scans demonstrated an enlarged spleen in both instances. The scan of the first patient (Fig. 3A) showed enlargement a little below the left costal margin and a narrow projection along the lateral abdominal wall. The scan of the second patient (Fig. 4A) showed bulky enlargement without extension below the left costal margin. Lacking a spleen scan, these 2 patients with polycythemia vera would have been considered as having normal spleens. Calabresi and Meyer,¹ and Szur *et al.*¹⁰ have described splenomegaly in three-fourths of their cases, while Wintrobe¹³ has reported a 90 per cent incidence of splenomegaly in his series of polycythemia vera cases. It is possible that a substantial portion of the 10-25 per cent polycythemia vera cases found to be without any palpable spleen might reveal splenic

enlargement on scanning. There is no doubt that spleen scans can provide definite evidence of the presence or absence of an enlarged spleen in polycythemia vera.

SUMMARY

The usefulness of spleen scans in the selection of an area of the spleen for further radiation therapy in a refractory patient with chronic myeloid leukemia is demonstrated.

Estimation of the degree of reduction of spleen size in response to treatment of patients with chronic myeloid leukemia, Hodgkin's disease and polycythemia vera is described as is the disappearance of a Hodgkin's mass following endoxan therapy.

The value of spleen scans in detecting the presence or absence of splenomegaly in cases of polycythemia vera without a palpable spleen is also discussed.

S. M. Sharma, M.B.B.S.
Radiation Medical Centre
Tata Memorial Hospital
Parel, Bombay-12
India

REFERENCES

1. CALABRESI, P., and MEYER, O. O. Polycythemia vera. I. Clinical and laboratory manifestations. II. Course and therapy. *Ann. Int. Med.*, 1959, 50, 1182-1216.
2. FISCHER, J., SEVERIN, G., and WOLF, R. Die Stellung der Szintigraphie im Rahmen der radiologischen Milzdiagnostik. *Acta radiol.*, (Diag.), 1965, 3, 278-286.
3. FISCHER, J., and WOLF, R. Results of clinical applications of scintillation scanning of spleen in 500 patients: possibilities and limits. Medical Radioisotope Scanning. Volume II. Symposium proceedings. I.A.E.A., Vienna, 1964.
4. GYFTAKI, H., PRONKAKIS, C., BINOPOULOS, D., ELIAS, C., and ALEVIZON, V. Photoscanning of the spleen by heat treated Cr⁵¹ labeled erythrocytes in congenital haemolytic anaemias. Medical Radioisotope Scanning. Volume II. Symposium proceedings. I.A.E.A., Vienna, 1964.
5. HARRIS, I. M., McALISTER, J. M., and PRANKERD, T. A. Relationship of abnormal cells to normal spleen. *Clin. Sc.*, 1957, 16, 223-230.
6. JOHNSON, P. M., HERION, J. C., and MOORING, S. L. Scintillation scanning of normal human spleen utilizing sensitized radioactive erythrocytes. *Radiology*, 1960, 74, 99-101.
7. PATERSON, R. The Treatment of Malignant Disease by Radium and X-rays. First edition. Edward Arnold & Co., London, 1956.
8. SHAH, K. D., NEILL, C. A., WAGNER, H. N., JR., and TAUSSIG, H. B. Radioisotope scanning of liver and spleen in dextrocardia and in situs inversus with levocardia. *Circulation*, 1964, 29, 231-241.
9. SHARMA, S. M., and RAMANATHAN, P. Economic method of obtaining photoscan. *Internat. J. Appl. Rad. & Isotopes.*, 1965, 16, 668.
10. SZUR, L., LEWIS, S. M., and GOOLDEN, A. W. Polycythaemia vera and its treatment with radioactive phosphorus: review of 90 cases. *Quart. J. Med.*, 1959, 28, 397-424.
11. WAGNER, H. N., JR., McAFEE, J. G., and WINKELMAN, J. W. Splenic disease diagnosis by radioisotope scanning. *A.M.A. Arch. Int. Med.*, 1962, 109, 673-684.
12. WAGNER, H. N., JR., WEINER, I. M., McAFEE, J. G., and MARTINEZ, J. I-Mercury-2-hydroxypropane (MHP): new radiopharmaceutical for visualization of spleen by radioisotope scanning. *A.M.A. Arch. Int. Med.*, 1964, 113, 696-701.
13. WINTROBE, M. M. Clinical Hematology. Fifth edition. Lea & Febiger, Philadelphia, 1962.

