

30. Mayr, H. G., Harns, I., Spencer, N. W., Hedin, A. E., Wharton, L. E., Porter, H. S., Walker, J. C. G. and Carlson, H. C., *Geophys. Res. Lett.*, 1979, 6, 447-450.
 31. Herraro, F. A., Spencer, N. W., Mayr, H. G., *Adv. Space. Res.*, 1992, 13, 201-220.

ACKNOWLEDGEMENTS. Thanks are due to Prof. R. Raghavarao for making available some of his recent results on ETWA-related processes.

Received 22 December 1992; accepted 6 January 1993

RESEARCH COMMUNICATIONS

Endomyocardial fibrosis is possibly an interstitial heart disease

C. C. Kartha

Division of Pathology, Sree Chitra Tirunal Institute for Medical Sciences and Technology, Thiruvananthapuram 695 011, India

To obtain clues to the pathogenesis of endomyocardial fibrosis (EMF), autopsy material from 42 patients and biopsy specimens from 89 patients were studied histologically. When full blown EMF was present in one cardiac ventricle, the contralateral ventricle with either focal lesions or no visible lesions, had interstitial fibrosis associated with increase in interstitial cellularity. It is suggested that EMF may be a reactive and progressive interstitial fibrosis, a result of cardiac fibroblast growth, with or without proliferation and enhanced collagen synthesis.

SINCE Gopi's¹ discovery of the prevalence of endomyocardial fibrosis (EMF) in Kerala, the disease has been extensively characterized in terms of clinical, radiological and echocardiographic features². The pathological profile of the disease in Kerala has also been described in detail^{3,4}. However, the pathogenesis of the disease remains unclear and the early lesion elusive. In the study reported here, pathological material has been analysed to obtain evidence of early or active lesions and identify histological features which would provide clues to the pathogenetic mechanisms.

Autopsy material from 42 patients who died of EMF and biopsy specimens from 89 patients with EMF, who underwent endocardiotomy and valve replacement from 1981 to 1991, form the basis of this study. The hearts at autopsy were examined in detail for gross lesions of the endocardium, myocardium, valves and coronary arteries. Paraffin sections from tissue blocks, representing all chambers of the heart, including the uninvolved portions, stained with haematoxylin and eosin were available from autopsy material. Biopsy material from operated patients also included right ventricular specimens from 27 patients with left ventricular disease.

In the absence of a gold-standard for early or active

EMF, early disease was suspected in young patients, and in contralateral ventricles with either visible focal lesions or absence of visible lesions, when extensive disease was present in one ventricle. Patients were divided into two groups, viz. those up to the age of 13 years and those above the age of 13 years.

Histologic criteria evaluated were: (1) nature of collagen, (fibrillar or hyalinized), cellularity, inflammation and calcification in the endocardium, (2) degenerative or hypertrophic changes in the myocardium, (3) cellularity (inflammatory or fibroblastic) and fibrosis (pericellular, perivascular, plexiform or scars) in the interstitium, and (4) vascular lesions (arteritis, mural thickening).

The plan was to observe whether in 'suspected early EMF' pathogenetic clues, viz. myocyte necrosis, inflammatory lesions, small vessel disease or endocardial thrombosis, were present.

The details of specimens reviewed in the study, classified in terms of ventricular involvement of the disease as well as age and sex of the patients, are given in Tables 1 and 2. Histologic features in autopsy specimens, depending on the age of patients, are summarized in Table 3. No significant difference was observed between the two age groups. Also, when extensive disease was present in one ventricle, the contralateral ventricle with either mild or no visible

Table 1. Details of autopsy specimens (N=42)

	Age 0-13 years		Age > 13 years	
	Male	Female	Male	Female
BV EMF	1	1	0	1
With valve disease	0	0	3	1
LV EMF				
No RV lesion	0	0	2	1
Focal RV lesion	1	1	3	6
With TOF	0	0	1	0
RV EMF				
No LV lesion	5	0	6	3
Focal LV lesion	0	0	0	1
With valve disease	1	0	2	2

BV, Biventricular; EMF, endomyocardial fibrosis; LV, left ventricle; RV, right ventricle; TOF, tetralogy of Fallot.

lesion, did not show necrotic, thrombotic, vascular or inflammatory lesions. The predominant form of fibrosis in the myocardium was interstitial.

Autopsy specimens from ventricles with either focal lesions or no visible lesions, and also right ventricular biopsies from patients with left ventricular EMF, revealed interstitial fibrosis and increase in interstitial cellularity (Tables 4 and 5). The interstitial cells were not inflammatory but resembled cardiac fibroblasts. These cells were seen either as diffuse infiltration (Figure 1a) or in focal aggregates (Figure 1b and c). Mild thickening of the endocardium with interstitial fibrosis extending into the subendocardium was observed in one specimen.

There are essentially two views on the pathogenesis of EMF. Overlapping pathologic features observed in Loeffler's endomyocardial disease and EMF have prompted the suggestion that the two are different ends of the same spectrum. Eosinophil-mediated myocardial injury would induce necrosis and set the stage for endocardial thrombosis which would heal and lead to the fibrotic stage of the disease⁵. The second view attributes endocardial fibrosis as a form of replacement

fibrosis of parietal endocardium secondary to subendocardial myofibre atrophy due to coronary arterial changes of as yet unknown aetiology⁶.

Our present study as well as earlier investigations⁷⁻⁹ have contributed little to support either of the above two views or the contention that EMF is a sequel to a pancarditis of undetermined aetiology. However, the observation of increased interstitial cellularity and interstitial fibrosis in one ventricle with focal or no visible lesion, when the other ventricle is affected by

Table 2. Details of biopsy specimens (N = 89)

	Age 0-13 years		Age > 13 years	
	Male	Female	Male	Female
BV EMF	0	0	5	7
LV EMF				
No RV biopsy	0	0	4	5
RV biopsy	2	1	5	19
RV EMF	4	3	16	18
	6	4	30	49

EMF, Endomyocardial fibrosis; LV, left ventricle; RV, right ventricle; BV, biventricular.

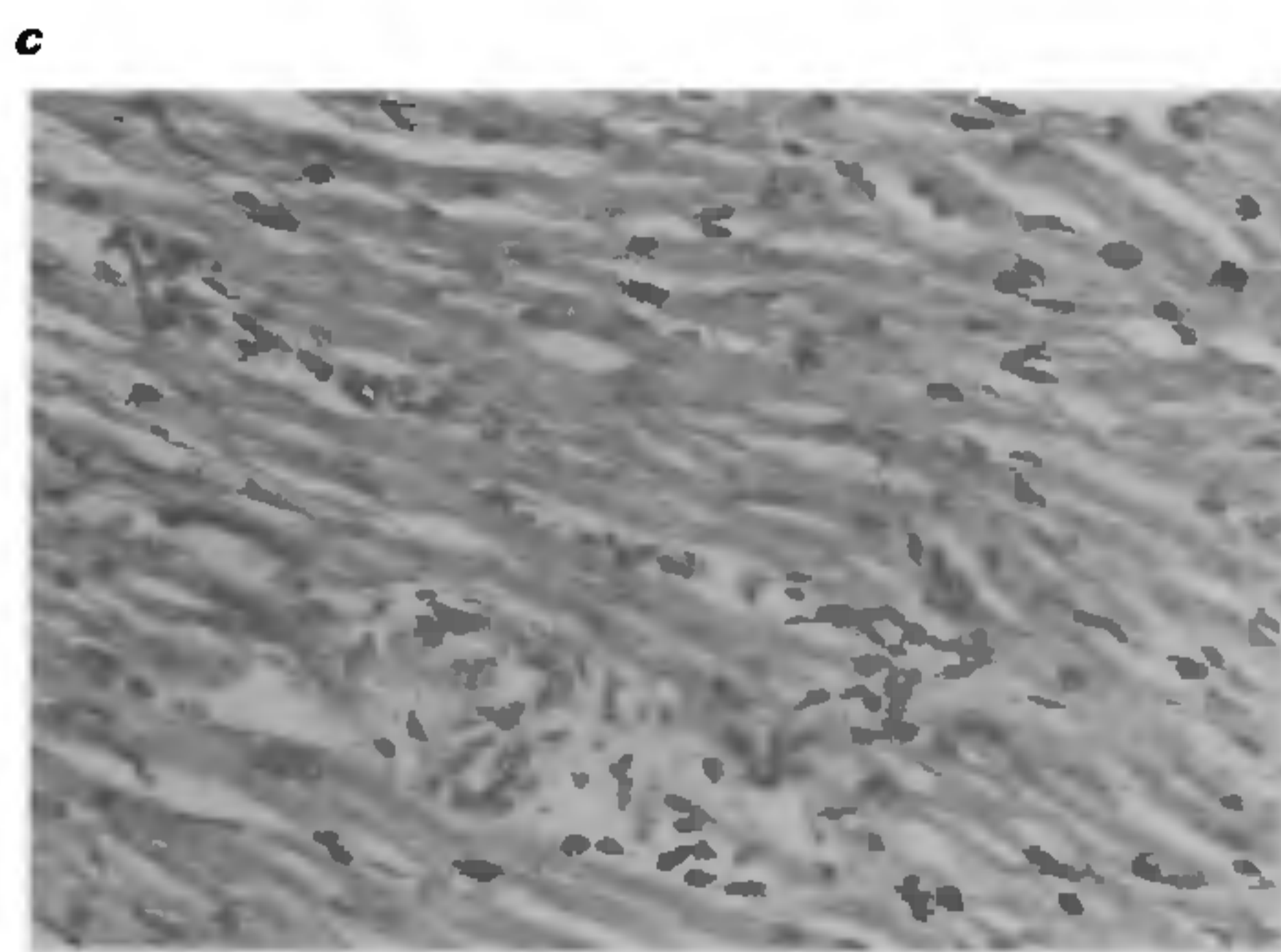
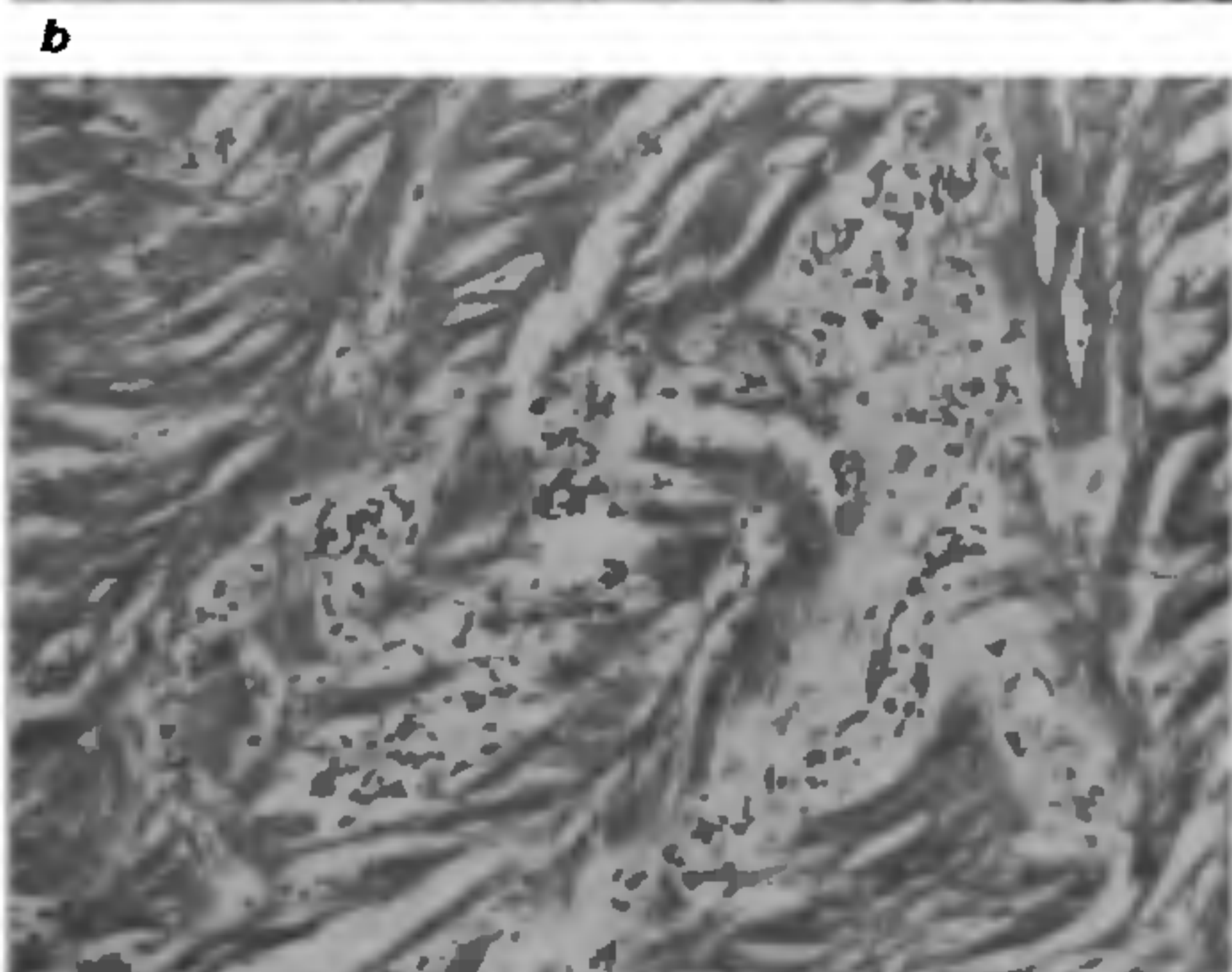
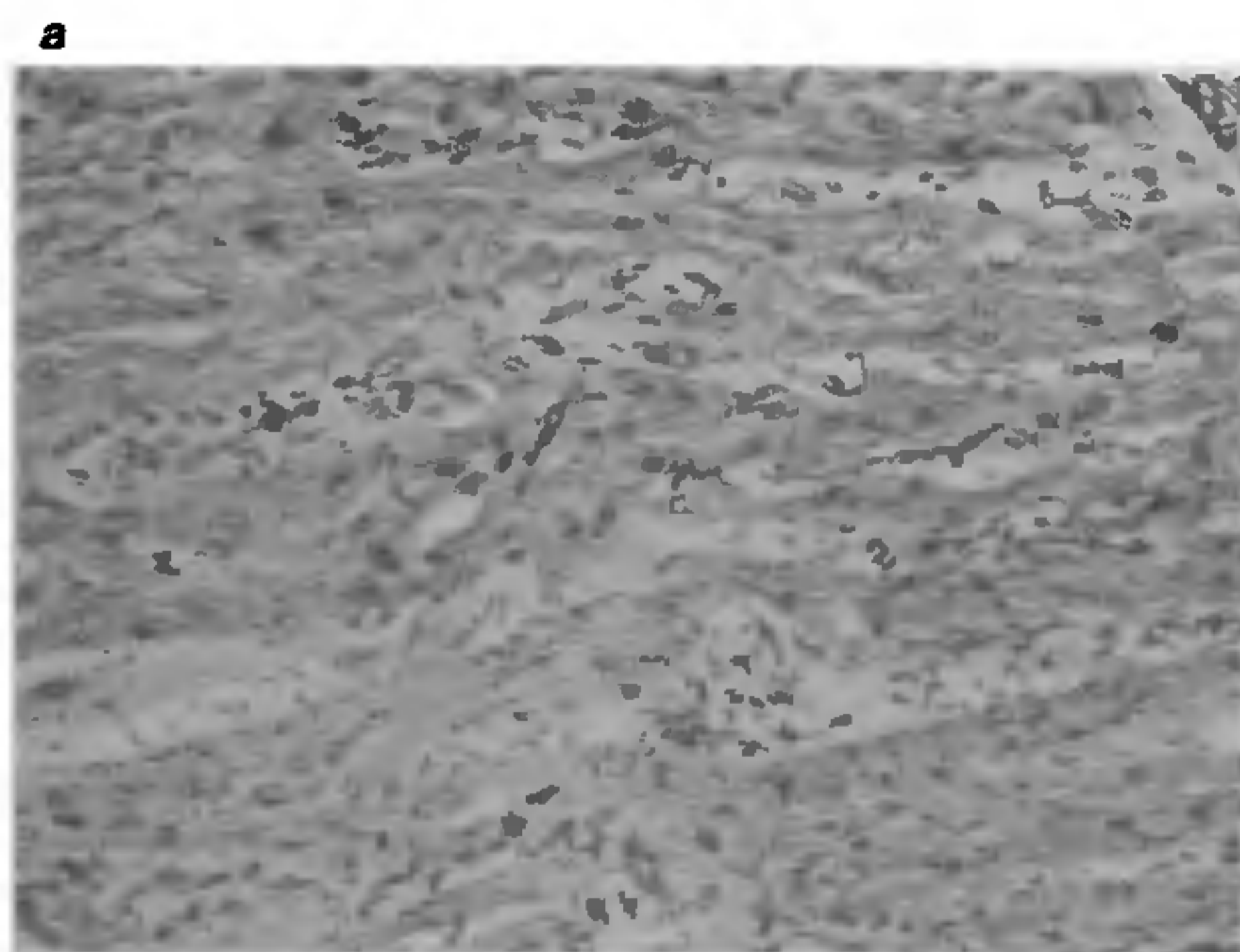


Figure 1a-c. Photomicrographs of interstitial cellularity in the myocardium. a, Diffuse infiltration of interstitial cells (haematoxylin-eosin, $\times 100$); b & c, Focal aggregates of interstitial cells (haematoxylin-eosin, $\times 100$).

RESEARCH COMMUNICATIONS

Table 3. Histologic features in autopsy specimens

	Age 0-13 years	Age > 13 years
	N = 10	N = 32
Endocardium		
Cellularity	1	4
Inflammation	4	9
Calcification	2	10
Myocardium		
Myocytolysis	5	19
Myofibre hypertrophy	6	31
Interstitial fibrosis		
Pericellular	4	27
Perivascular	3	9
Plexiform	1	10
Scars	4	15
Vascular lesions	3	19
Lymphatic dilatation	2	11

Table 4. Histologic features in autopsy specimens

	No.	Cellular proliferation			
		Endocardial		Interstitial	
		0-13	>13	0-13	>13 years
LV EMF with focal RV lesion	11	1	1	2	2
LV EMF with no RV lesion	3	0	0	2	1
MVD with focal RV lesion	5	0	1	1	2
RV EMF with focal LV lesion	1	0	0	0	1
RV EMF with no LV lesion	14	0	0	0	3

LV, left ventricle; RV, right ventricle; EMF, endomyocardial fibrosis; MVD, mitral valve disease.

Table 5. Histologic features in right ventricular biopsies from patients with left ventricular EMF

	Number
LV EMF with RV biopsy	27
Myocardium not seen	5
RV within normal limits	13
Lesions	9
Interstitial fibrosis	8
Interstitial cellularity	6
Endomyocardial fibrosis	4

EMF, Endomyocardial fibrosis; LV, Left ventricle; RV, Right ventricle.

EMF could be an important clue in understanding the pathogenesis of EMF. A similar finding has earlier been reported in biopsy studies in patients with EMF¹⁰. Also, Connor *et al.*⁶ have found in early stages of EMF, studied at autopsy, increased accumulation of mucopolysaccharides, increased collagen and small foci of fibrosis with scanty inflammatory infiltrate. No serious attention has been paid to the possible significance of these observations. The increase in interstitial cellularity and interstitial matrix components along with predominant perivascular and interstitial fibrosis, in the absence of significant myofibre lesions and inflammation, suggest that EMF is an interstitial disease, a reactive stromal change.

Interstitial and perivascular fibroses are frequently seen in reactive types of fibrosis accompanying myocardial hypertrophy, e.g. renovascular hypertension and atrophy, e.g. kwashiorkor¹¹. The restrictive haemodynamics and macroscopic features of EMF, such as ventricular obliteration associated with retraction of ventricular walls, are quite distinctive from the haemodynamics and morphology of any form of reparative or replacement fibrosis. They do not resemble the morphologic spectrum of heart lesions seen in healing of infarcts, post-inflammatory scarring (e.g. myocarditis of diverse aetiology), post-degenerative replacement, and healing of toxic necrosis, all of which lead to scars and ventricular dilatation with poor myocardial contractility as well as loss of systolic function.

Morphologic features of EMF are found in the late stages of Loeffler's endomyocardial disease and occasionally in toxicity due to anthracyclines and methysergide^{5,12,13}. Recent studies have shown that the eosinophils contain, in addition to the cytotoxic major basic protein, transforming growth factor, a potent stimulant for fibroblast growth¹⁴. Methysergide toxicity is associated with aggressive fibrosis in other regions like mediastinum and retroperitoneum¹⁵, and by virtue of its chemical structure, which is closely related to that of serotonin, can cause direct stimulation in the growth of fibroblasts¹⁶. Anthracyclines also produce cardiac

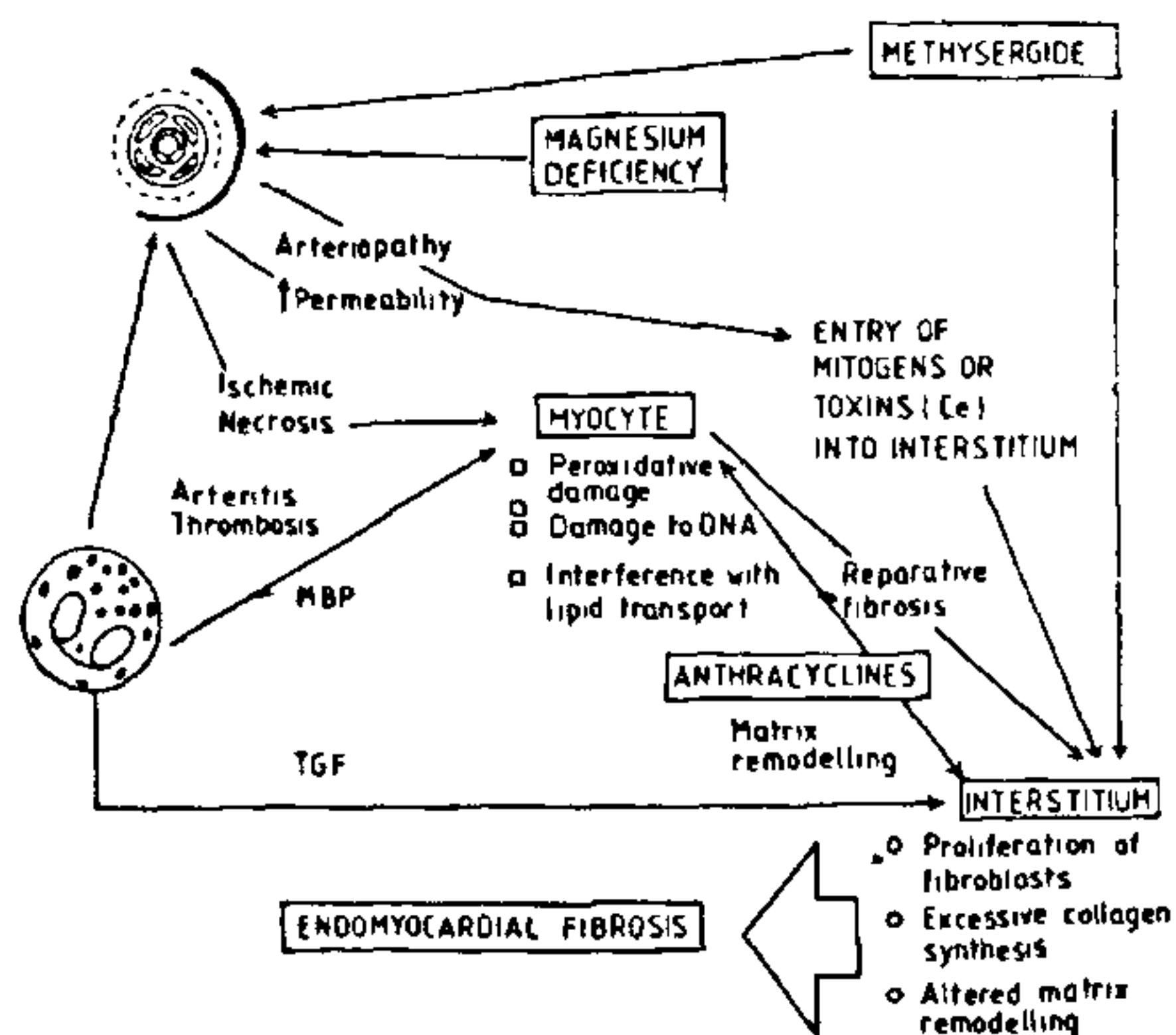


Figure 2. Pathways through which a morphologic picture of EMF could result from diverse causes. TGF, transforming growth factor; MBP, major basic protein; Ce, cerium; DNA, deoxyribonucleic acid.

interstitial injury and matrix remodelling in addition to their myocytotoxic actions¹⁷. It would seem that EMF results in those instances where the interstitial injury and response of the cardiac fibroblasts overwhelm injury to the myocardial cell and/or the microcirculation. Figure 2 summarizes the pathways through which a morphologic picture of EMF could result from diverse causes.

In conclusion, it is suggested that EMF is an interstitial disease and that the cardinal feature is abnormal stimulation of cardiac fibroblasts leading to enhanced collagen synthesis. Entry of trophic factors into the interstitium could be mediated by injury to the microcirculation and alterations in permeability. Myocytolysis seen in EMF is a minor component and could be caused by a combination of entrapment by fibrosis and toxicity by the same factors which produce the interstitial injury.

1. Gopi, C. K., *Bull WHO*, 1968, 38, 978-991.
2. Valiathan, M. S., Balakrishnan, K. G. and Kartha, C. C., *Indian J. Paediatr.*, 1987, 54, 229-236.
3. Kartha, C. C. and Sandhyamani, S., *Indian J. Med. Res.*, 1985, 82, 439-446.

4. Kartha, C. C. and Valiathan, M. S., *Indian J. Med. Res.*, 1988, 87, 275-282.
5. Olsen, E. C. G. and Spry, C. J. F., *Progress in Cardiology*, (eds. Yu, P. and Goodwin, J. F.), Lea and Febiger, Philadelphia, 1979, vol. 8, pp. 281-303.
6. Connor, D. H., Somers, K., Hutt, M. S. R., *Am. Heart J.*, 1968, 75, 107-124.
7. Shibu, S., Kartha, C. C., Basu, D. and Appukuttan, P. S., *Indian J. Med. Res.*, 1986, 84, 191-194.
8. Kartha, C. C., Mathai, A., Balakrishnan, K. G. and Valiathan, M. S., *Indian Heart J.*, 1984, 36, 90-91.
9. Mathai, A., Kartha, C. C. and Balakrishnan, K. G., *Indian Heart J.*, 1986, 38, 470-472.
10. Somers, K., Hutt, M. S. R., Patel, A. K. and D'Arbela, P. G., *Br. Heart J.*, 1971, 33, 822-832.
11. Weber, K. T. and Brilla, C. G., *Circulation*, 1991, 83, 1849-1865.
12. Fitter, W., DeSa, D. J. and Pai, K. R. M., *J. Clin. Pathol.*, 1981, 34, 602-605.
13. Harbin, A. D., Gerson, M. C. and O'Connell, J. B., *J. Am. Coll. Cardiol.*, 1984, 4, 196-199.
14. Wong, D. T., Weller, P. F., Galli, S. J., *J. Exp. Med.*, 1990, 172, 673-681.
15. Schwartz, F. D., Dunea, G. and Kark, R. M., *Am. Heart J.*, 1966, 72, 843-844.
16. Boucek, R. J. and Alvarez, T. R., *Science*, 1970, 167, 898-899.
17. Caulfield, J. B. and Bittner, V., *Am. J. Pathol.*, 1988, 133, 298-305.

Received 14 October 1992; accepted 6 January 1993

Differential aggression towards alien conspecifics in a primitively eusocial wasp

Arun B. Venkataraman and Raghavendra Gadagkar

Centre for Ecological Sciences, Indian Institute of Science, Bangalore 560 012, India

When the members of a colony of the primitively eusocial wasp *Ropalidia marginata* were removed from their nests and introduced into a cage containing an alien colony, the resident wasps in the cage treated different classes of introduced animals differently. The young (<8 days old) introduced animals were allowed to join the resident colony without any aggression. The queen amongst the introduced animals was immediately attacked and killed. Of the remaining animals, some were killed depending on how much time they had spent away from their natal nests before introduction. These results suggest that aggression may be directed towards aliens based on the perception of reproductive threat from them.

ROPALIDIA MARGINATA (Lep.) (Hymenoptera: Vespidae) is a primitively eusocial Polistine wasp abundantly distributed in peninsular India. New colonies are initiated, throughout the year, by one or a group of female wasps. Even in the latter, only one individual lays eggs while the remaining work towards building the nest, brood care and foraging. Daughters who

eclose from these nests may either leave to found their own new single or multiple foundress nests or may stay back and take on the role of workers. Although there is only one queen at any given time, queen replacements are common so that workers, both in pre-emergence as well as in post-emergence colonies, have opportunities to take over their colonies as replacement queens. The colonies are perennial so that workers eclosing at any time have more or less equal opportunities to become reproductives either in newly founded colonies or in their natal colonies^{1,2}.

A question of obvious interest is why so many *R. marginata* females work in someone else's nest rather than start their own solitary foundress nests? The three main factors that might select for such worker behaviour over solitary nest founding, suggested in the literature, have to do with a) opportunities to rear brood more closely related than one's own offspring^{3,4}, b) parental manipulation of some individuals into sub-fertility^{5,6}, and c) mutualistic interactions between individuals with or without high genetic relatedness to harness the ecological advantage of group living⁷.

Polyandry (multiple mating by queens) and serial polygyny (queen replacements) reduce worker-brood genetic relatedness to such an extent in *R. marginata* that the worker strategy could not possibly be selected because of opportunity to rear very closely related brood⁸⁻¹¹. There is some pre-imaginal caste-bias but at least 50% of eclosing females are potentially capable of