

Original Article-II

Mediastinal Masses- the Bad, the Ugly and the Unusual!

PRASANTH GANESAN, AMUL KAPOOR, JYOTI BAJPAI, SHIPRA AGARWAL, SANJAY THULKAR AND LALIT KUMAR

ABSTRACT:

Background: Differential diagnosis of mediastinal masses is wide and management of individual cases can be challenging. In addition to common malignancies e.g. lymphomas and thymomas. Many other benign and malignant conditions can present with mediastinal masses.

Patients and Methods: We describe five patients with a diagnosis of mediastinal mass. We wish to showcase the range of diagnosis possible in these situations. This is followed by a brief discussion on the general approach to such cases.

Conclusion: A good history, detailed careful clinical examination, judicious use of imaging and investigations e.g. blood counts and tumour makers can give a vital clue to the diagnosis of mediastinal mass.

INTRODUCTION

Mediastinal masses are a commonly encountered problem in the clinic. Even though majority of these are caused by benign conditions, many of them asymptomatic, a significant proportion of these can be caused by malignant etiology.¹ An interesting and clinically relevant feature of the mediastinal tumours is that many of them are amenable to treatment including curative chemotherapy. Despite being common, the diagnosis in an individual case can be challenging. Here we present 5 cases of mediastinal tumours- three of which are fairly common, two of them very rare. We aim to

highlight some unusual entities that present as mediastinal masses as well as the unusual presentations of some common tumours.

Case 1: Mr. JK, a 23 year old male student presented with a 2 month history of low grade fever and progressive breathlessness. On admission he was dyspnoeic, had features of superior vena caval (SVC) obstruction, bilateral cervical and axillary lymphadenopathy, and massive right-sided pleural effusion. Investigations: Hb-10.2gm%, WBC-17900/cmm. Platelets: 187000/cmm; Peripheral smear: no atypical cells. Bone marrow normocellular, with no increase in blasts or atypical cells. Chest x-ray (figure 1) showed bilateral pleural effusion and mediastinal widening. CT scan chest (fig. 1) revealed extensive prevascular and paratracheal lymph nodes (largest 11.4X8.5cm) encasing great vessels, and bilateral pleural effusion. CT scan abdomen-normal. Pleural fluid cytology extensive sheets of atypical lymphoid cells. Biopsy of the axillary lymph node suggested replacement by monophasic immature lymphoid cells expressing T-cell markers (CD3+ CD20-). He was diagnosed as having diffuse large cell lymphoma of T cell immunophenotype.

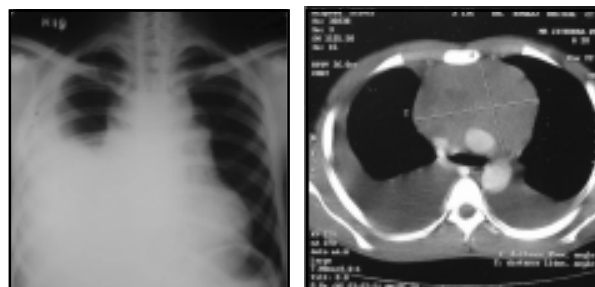


Figure 1 a Chest x-ray PA view showing mediastinal mass with left massive pleural effusion. B) CECT chest shows an anterior mediastinal mass with areas of necrosis and bilateral pleural effusions

Department of Medical Oncology, Pathology (Shipra Agarwal), Radiodiagnosis (Sanjay Thulkar), Institute Rotary Cancer Hospital, All India Institute of Medical Sciences, New Delhi-29
Correspondence to: LALIT KUMAR
E-mail: lalitaiims@yahoo.com

Case 2: Mrs. SD, a 27-year-old female presented with progressive dyspnoea of one year duration. clinical examination was unremarkable with no peripheral lymph nodes or specific chest findings. Blood counts were normal. Serum β -HCG, AFP and LDH were within normal limits. Chest x-ray (figure 2a) showed mediastinal widening. CT scan chest revealed (fig, 2b) 7X5 cm soft tissue density mass in the retro-carinal region extending inferiorly upto the right medial basal segment. The lung parenchyma and abdomen was normal. Biopsy from the mass (figure 3) showed lymphoid follicle formation, regression of germinal center with vascularisation of the center and extensive hyalinisation suggestive of Castleman's Disease (hyaline vascular variant).

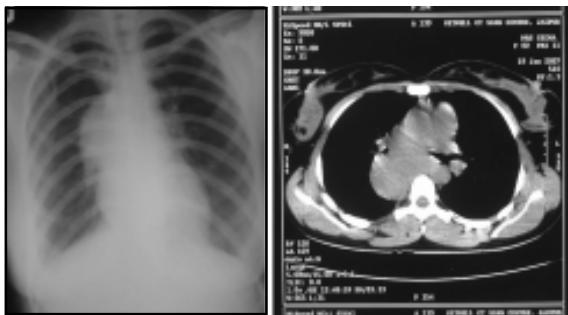


Figure 2: a) Chest x-ray shows mediastinal widening; b) CT scan of the chest :there is a soft tissue density mass in the retro-carinal region

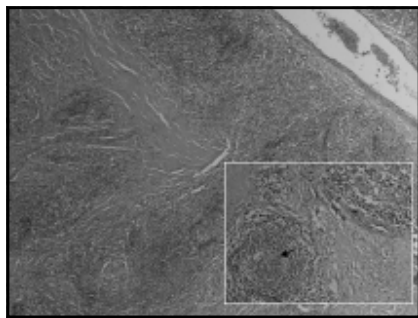


Figure 3: H & E (40 X) showing lymphoid follicle formation, regression of germinal center with vascularisation of the center (arrow) and extensive hyalinisation (inset 100X)

Case 3: Mr. JS, a 29 year old male had a chest x-ray taken as part of his work up of non-specific arthritis. He had no chest symptoms. His general examination was unremarkable. The x-ray (figure 4a) showed mediastinal widening by a smooth walled mass with a fine line of curvilinear calcification at periphery. CT scan

chest (Fig. 4b) showed an anterior mediastinal homogenous mass with a rim of calcification. Pleural-based deposits were also noted. There was loss of fat plane between the mass and the pericardium suggesting invasiveness. Biopsy (fig. 5) showed a neoplasm consisting of large cells with moderate amount of cytoplasm (cytokeratin positive) in a background of CD3+ve lymphocytes. Overall features were suggestive of an invasive thymoma.

Case 4: Mr. CL, a 42-year-old male presented with right-sided chest pain of 3 months duration. He had undergone prior evaluation

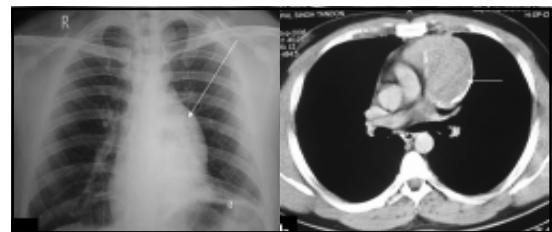


Figure 4. a) Chest x-ray PA view showing a posterior mediastinal mass. The right heart border is not silhouetted. b) MRI of the chest showing a paravertebral mass in the posterior mediastinum

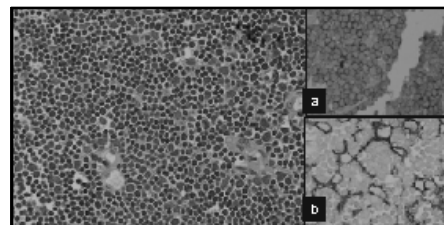


Fig. 5: (H&E, 100X) shows two types of tumour cells; the predominant population is of lymphoid cells (3a) which are CD3+ and interspersed among these are epithelial cells (3b) which express cytokeratin (fig 3 100X; 3a IHC for CD3;3b IHC for Cytokeratin)

with Chest x-ray and MRI of the chest. His Chest x-ray (figure 6a) showed right-sided mediastinal mass not silhouetting the right cardiac border (posterior mediastinal mass). On the MRI (figure 6b), there was a large mass of homogenous signal intensity located in the posterior mediastinum, with irregular enhancement after contrast. On evaluation at our center he was found to have long standing history of anemia and jaundice and a positive family history of the same. On examination he had pallor, icterus and a moderate splenomegaly. There were no specific chest findings. A clinical diagnosis of hemolytic anemia was made.

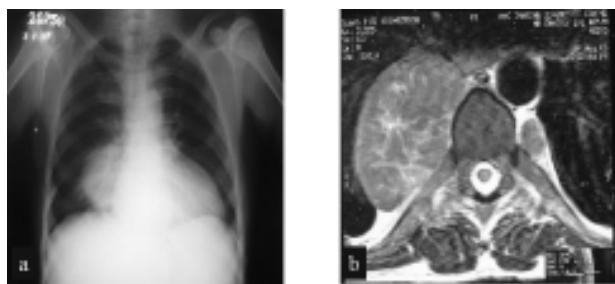


Fig. 6. a) Chest x-ray PA view showing a posterior mediastinal mass. The right heart border is not silhouetted. b) MRI of the chest showing a paravertebral mass in the posterior mediastinum

Investigations Hb 6.4 G/dL, WBC: 9800/cmm, platelets: 153000 cmm. Serum bilirubin: 3.3 mg/dL (predominantly unconjugated), normal liver enzymes and renal parameters. Peripheral smear was consistent with picture of hemolytic anemia. Hemoglobin electrophoresis: Hb F: 18.3%, HbA 7.8%, Hb A2: 68.5% and HPLC (fig. 7) showed Hemoglobin E beta thalassemia (thalassemia intermedia). An extramedullary focus of hematopoiesis was suspected- which was confirmed by fine needle aspiration cytology (fig. 8).

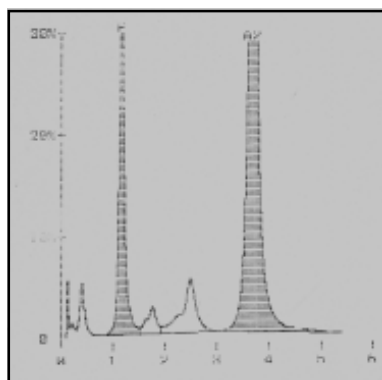


Fig. 7: Hemoglobin electrophoresis showing two peaks at HbF and HbA2

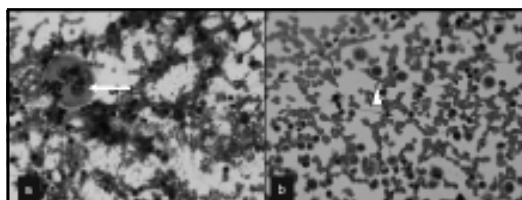


Fig. 8: Microphotograph showing preserved megakaryocyte (arrow) along with immature eosinophilic precursors, erythroid cells (arrow head) besides other immature cells in a haemorrhagic background

Case 5: Mrs. VD, a 25 year old lady presented with breathlessness and right sided chest pain for 7 months. She had past history of right breast lump, which had been excised at about a year back (Histopathology at that time had been reported as atypical epithelial hyperplasia associated with fibrocystic disease). She was referred to us because the Chest x-ray had shown Mediastinal widening. On clinical examination she was found to have residual right breast lump in the upper outer quadrant. Her blood counts biochemical parameters (including β -HCG, AFP and LDH) were normal. Her chest imaging (fig. 9) showed a large anterior Mediastinal mass with areas of hemorrhage and necrosis. Biopsy

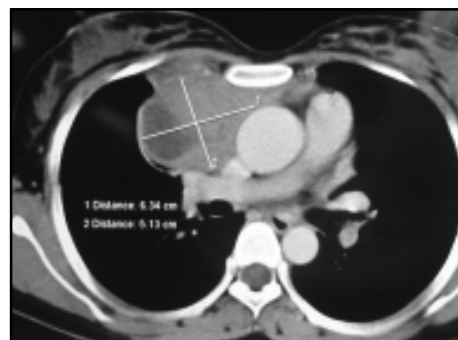


Fig. 9: Anterior mediastinal mass with areas of necrosis.

from the mass showed fibrocollagenous tissue infiltrated by islands of malignant cells, gland formation. The cells were stained positive for Cytokeratin. The overall features were consistent with metastasis from a primary breast carcinoma. The slides of her original breast lump excision were reviewed and found to be consistent with Invasive ductal carcinoma (fig. 10).

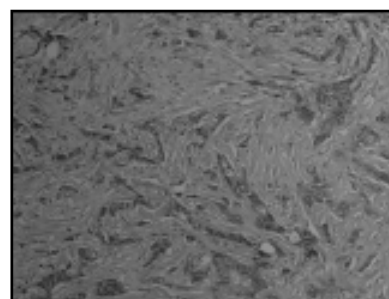


Fig. 10: tumour cells infiltrating as cords and tubules in a sclerotic background

Table 1: Differential diagnosis of mediastinal masses based on their anatomic location

ANTERIOR MEDIASTINUM	MIDDLE MEDIASTINUM	POSTERIOR MEDIASTINUM
Thymoma	Lymphoma	Neurogenic tumour
Teratoma	Pericardial cyst	Bronchogenic cyst
Lymphoma	Bronchogenic cyst	Enteric cyst
Carcinoma	Metastatic cyst	Extra-medullary hematopoiesis
Parathyroid adenoma	Systemic granuloma	Xanthogranuloma
Intrathoracic goiter		Diaphragmatic hernia
Lipoma		Meningocele
Intrathoracic aneurysm		Paravertebral abscess
Lipoma		Meningocele
Intrathoracic aneurysm		Paravertebral abscess

DISCUSSION

Mediastinal masses can be caused by a variety of benign and malignant conditions. Though the differential diagnosis (table 1) is extremely wide, diagnosis in an individual case can be aided by thorough clinical examination and judicious use of imaging and ancillary investigations. The three important features

The location of mediastinal masses per se varies with age (table 2). This variation is due to the higher incidence of thymic tumours and lymphomas in adults and the neurogenic tumours in children.² In fact, age alone can assist us in narrowing the differential diagnosis of mediastinal masses to a great extent. In a young adult presenting with a mediastinal mass (as in case number 1), the most common

Table 2: Variation in the presentation in mediastinal masses based on the anatomic site with age (adapted from Azarow et al⁴)

	Adults	Children
Anterior mediastinum	54%	43%
Middle mediastinum	20%	18%
Posterior mediastinum	26%	40%

which aid the clinical differential of a mediastinal tumour are 1) the location in the mediastinum, 2) the age of the patient, and 3) the symptoms at presentation.

differentials to be considered would be T-cell lymphoblastic lymphomas and the Germ cell tumours. Even though no case of Germ cell is represented in the above series, they are to be considered in the evaluation of mediastinal

masses, especially in adolescent males.² Hence markers for germ cell tumours must be the part of the work of such cases.³ In elderly age groups many of the carcinomas present with secondary deposits in the mediastinum (Most common being lung cancer in men and breast cancer in women)¹

The third aspect of mediastinal tumours regards their presentation; 40% of mediastinal masses are asymptomatic. Interestingly, asymptomatic patients are more likely to have benign lesions, whereas symptomatic patients more often harbor malignancies. In a study by Davis et al, 85% of patients with a malignancy were symptomatic, but only 46% of patients with benign neoplasms had identifiable complaints.⁵ The most common symptoms of presentation of mediastinal tumours are with cough, dyspnoea, and chest pain. The presence

of SVC syndrome, Horner’s syndrome, hoarseness of voice (due to recurrent laryngeal nerve palsy) and phrenic nerve palsy are all suggestive of malignant etiology.⁶

One important neoplasm which can be completely asymptomatic and which, in 50-60% of the cases is diagnosed incidentally on chest x-rays (as in case no 3 above) done for other purposes is the thymoma.⁷

It is important to keep in mind common causes while evaluating mediastinal mass. Even though cases like 2&4 underscore the importance of keeping ourselves ready for surprises, common causes like Lymphoma, Germ cell tumours, Primary lung carcinoma, Retrosternal goiter, and thymoma are to be ruled out before considering alternate diagnosis. Table 3 aids in the clinical and radiological differential diagnosis of these common conditions.

Table 3. Differential diagnosis of some common mediastinal masses.

	Location in the mediastinum	Clinical features	Radiological features
1. Thymoma	Anterior	Mostly asymptomatic, Symptoms more in invasive thymomas; paraneoplastic syndromes (myasthenia, PRCA, connective tissue disorders) +/-	Homogenous solid masses; 1/3 rd hemorrhage/ necrosis; peripheral curvilinear calcification (20%), loss of fat plane suggests invasiveness
2. Lymphoma	Anywhere	B symptoms, Peripheral LNE, hepatosplenomegaly/ Altered blood counts in Lymphoblastic lymphomas.	Lobulated contour, hemorrhage +/-, necrosis +/-; effusions +/-
3. Retrosternal goiter	Anterior	Evident goiter in the neck.	Encapsulated, Lobulated, Heterogeneous, Continuity between cervical and mediastinal components
4. Germ cell tumours	Anterior/ Middle	Young adult, Cryptorchidism, elevated biomarkers.	Uniform contour, Necrotic areas common; calcification (sign of maturity) Effusions +/-
5. Secondaries from carcinomas	Middle	Elderly age group, symptoms related to the primary (lung, breast etc)	Usually in continuity with a lung primary; Hemorrhage and necrosis common
6. Neurogenic tumours	Posterior	Asymptomatic, Posterior chest wall pain, Neurofibromatosis, radicular pain, paraplegia (rare)	Continuity with the nerve sheath, widening of the intervertebral foramen, Intraspinal extension +/- (dumbbell tumours)

PRCA-pure red all aplasia, LNE-Lymphnode enlargement

The CT scan chest is the single most important diagnostic modality while evaluating mediastinal masses except for the posterior mediastinal tumours of “Neurogenic origin” (where MRI maybe useful).⁸ Moreover MRI scans are superior to CT in defining vascular involvement and in distinguishing recurrent tumour from radiation fibrosis. In addition to the accurate assessment of the nature of the mass (solid versus cystic), CT can also detects fat and calcium within the tumour mass. The relationship with the surrounding structures and the extent of invasion is also accurately assessed by the CT scan (very important in distinguishing invasive thymoma from the non-invasive entity) as seen in case 3. Fine needle aspiration cytology is considered as adequate evaluation and when done under guidance of USG/ CT the results are very good.⁹ However core biopsies are preferable whenever lymphoma or thymoma is suspected.

REFERENCES AND SUGGESTED READING:

1. Beau V, Duwe BV, Daniel H, Sterman DH and Musani, AI. Tumours of the Mediastinum. *Chest*. 2005;128:2893-909
2. Strollo DC, Rosado-de-Christenson ML, Jett JR, et al. Primary mediastinal tumours: Part 1. Tumours of the anterior mediastinum. *Chest* 1997;112:511,
3. Nichols, CR. Mediastinal germ cell tumours: clinical features and biologic correlates. *Chest* 1991;99:472-479
4. Azarow KS, Pearl RH, Zurcher R, Edwards FH, Cohen AJ. Primary mediastinal masses: a comparison of adult and pediatric populations. *J Thorac Cardiovasc Surg* 1993;106:67
5. Davis RD Jr, Newland Oldham H Jr, Sabiston DC Jr. Primary cysts and neoplasms of the mediastinum: recent changes in clinical presentation, methods of diagnosis, management and results. *Ann Thorac Surg* 1987;44:229-237.
6. Rice TW, Rodriguez RM, Light RW. The superior vena cava syndrome: clinical characteristics and evolving etiology. *Medicine (Baltimore)* 2006;85:37-42
7. Wright CD Panos F Choi NCH Shepard JO Hasserjian RP Case 16-2007: A 61- year old man with a mediastinal mass. *NEJM* 2007;356:2185-93
8. Strollo DC Rosado-de- Christensen ML Jett JR. Primary mediastinal tumours.Part II. Tumours of the middle and posterior mediastinum. *Chest* 1997;112:1344-57
9. Shabb NS, Fahl M, Shabb B, Haswani P, Zaatari G. Fine-needle aspiration of the mediastinum: a clinical, radiologic, cytologic, and histologic study of 42 cases *Diagn Cytopathol*. 1998;19:428-36

