

---

# Localization of glutamate in the human retina during early prenatal development

G JOTWANI, S WADHWA\*, T C NAG and S SINGHAL

Department of Anatomy, All India Institute of Medical Sciences, New Delhi 110 029, India

\*Corresponding author (Fax, 91-11-6862663; Email, swadhwa@medinst.ernet.in).

In this study we have localized glutamate (GLU) in fetal (14–25 weeks gestation, Wg) human retinas by immunohistochemistry. At 14 Wg, GLU-immunoreactivity (IR) was localized only in the central part of retina, showing a prominently labelled nerve fiber layer. A few ganglion cells and displaced amacrine cells were very weakly labelled. At 17 Wg, GLU was localized conspicuously in many ganglion cells, displaced amacrine cells, some amacrine cells and the prospective photoreceptor cell bodies in the neuroepithelial layer. With progressive development at 20 and 25 Wg, the IR for GLU was found additionally in the Müller cell endfeet, some bipolar cells as well as in the horizontal cells that were aligned in a row along the outer border of the inner nuclear layer of the central retina. The photoreceptor cell bodies in the outer nuclear layer were also prominently immunopositive for GLU. The developmental distribution of GLU in the human retina tends to indicate that it plays an important role in the differentiation and maturation of retinal neurons.

---

## 1. Introduction

The retina develops as an outgrowth of the diencephalon during early embryonic life. Although firm data on the temporal differentiation of various neurons of the human retina are still lacking, most workers have found by light microscopy that Müller cells and ganglion cells differentiate before 10 weeks of gestation, when they lie together in the inner neuroblastic zone (Mann 1964; O'Rahilly 1975; Rhodes 1979). The amacrine cells are formed in the course of development from the innermost rows of the outer neuroblastic zone at 11 weeks (Rhodes 1979). The photoreceptors which differentiate from the scleral rows of the outer neuroblastic zone are formed around 10–12 weeks; of these cones differentiate first at 10 weeks, followed by rods from 12 weeks of gestation onward (Hollenberg and Spira 1972; Rhodes 1979). Bipolar and horizontal cells differentiate somewhat late, around midgestation (18–20 weeks), from the outer neuroblastic zone (Rhodes 1979). The differentiation of the retina occurs in a vitreal to scleral direction and proceeds from centre (close to optic disc) to periphery.

Glutamate (GLU) is a major amino-acid neurotrans-

mitter of the vertebrate central nervous system (CNS). In the adult retina, it occurs in the primary vertical pathway, i.e., photoreceptor → bipolar → ganglion cells and mostly exerts excitatory transmission along this pathway (Massey 1990; Barnstable 1993). Several studies have pointed to a significant role for GLU during retinal development (Redburn *et al* 1992; Bodnarenko and Chalupa 1993; Pow *et al* 1994). It influences neuronal differentiation by exerting its trophic as well as excitotoxic effects (McDonald and Johnston 1990). Another interesting aspect relates to its involvement in synaptic pruning in developing retinas and readjustment of circuitry thereby (Bodnarenko and Chalupa 1993; Redburn and Rowe-Rendelman 1996). The present report is the first on the immunohistochemical localization of GLU in the prenatal human retina.

## 2. Materials and methods

Human fetuses of gestational ages 14–15 (2), 17–18 (3), 20–21 (2), 24–25 (1) weeks were collected from cases in which hysterectomy was performed for medical termination of pregnancy. Prior clearance of the ethics

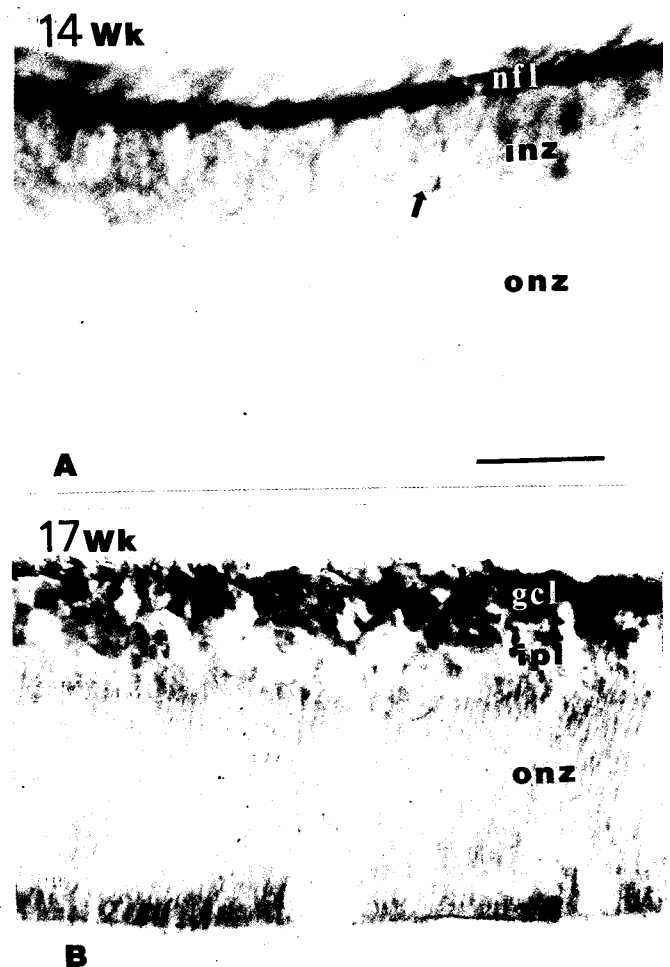
**Keywords.** Human; fetal retina; development; glutamate; immunohistochemistry

committee and consent of parents involved were sought for use of the fetuses for research. Their age was determined by crown-rump length (Hamilton *et al* 1962) and biparietal diameter. The eyecups were fixed in 2.5% glutaraldehyde in 0.1 M phosphate buffer (PB, pH 7.4) for 2 days at 4°C. The retinas were cryoprotected in 30% sucrose overnight, cut into 30 µm thick sections on a cryostat (Reichert Jung) and stored in cold PB. Retinal sections from age groups 20–21 and 24–25 weeks were also used in the study of gamma amino butyric acid (GABA) expression in the fetal human retinas (Nag and Wadhwa 1997). For glutamate immunohistochemistry, the sections were initially treated in 0.1 M sodium borohydride in PB for reduction of glutaraldehyde. Nonspecific reactions were blocked by incubating them in 10% horse normal serum for 3 h at 4°C. Sections were then incubated in the primary antibody against GLU (1 : 1000; monoclonal, Incstar, Minnesota, USA) for 2 days at 4°C. The secondary antibody incubation was done in biotinylated horse anti-mouse IgG (Vector Laboratories, Burlingame, USA; dilution 1 : 200) for 5 h at 4°C. After washing, the sections were put in avidin-biotin peroxidase complex (dilution 1 : 100; Vector) for 2 h at room temperature. For visualization of immunoreactivity (IR), the sections were treated in 0.03% diaminobenzidine tetrahydrochloride (Sigma, USA) in 0.1 M acetate-imidazole buffer containing 0.05% H<sub>2</sub>O<sub>2</sub> and 0.3% nickel sulphate, for 20 s. Finally, the sections were mounted onto gelatin-coated slides and dehydrated in ethanol. In control sections, incubation in the primary antibody was omitted.

### 3. Results

At 14–15 Wg, GLU-IR was localized only in the central part of the retina, showing a prominently labelled nerve fiber layer (nfl, figure 1A). A few ganglion cells and displaced amacrine cells were very weakly labelled at this fetal stage. Faint to no GLU-IR was observed in the midperipheral and peripheral retina, respectively. At 17–18 Wg, many ganglion cells as well as displaced amacrine cells were found to be conspicuously labelled in the midperipheral retina (figure 1B). There was also faint impression of IR development in the differentiating amacrine cells along the inner border of outer neuroblastic zone and in the prospective photoreceptor cell bodies in the neuroepithelial layer of the retinal sections examined. The gradient of immunoreactivity noted from central to peripheral retina was more evident from this age group onwards. At 20–21 Wg, in addition to the ganglion and displaced amacrine cells in the ganglion cell layer of the retina, the Müller cell endfeet, some amacrine and bipolar cells, as well as almost all horizontal cells that were aligned in a row along the outer border of the inner nuclear layer, close to the prospective foveal region, were labelled for GLU. Many photoreceptor cell bodies

were faintly immunoreactive only near the central retina (figure 2B). Adjacent retinal section, stained with haematoxylin and eosin, had revealed all retinal layers with their cells to be well-formed (figure 2A). The identification of various cell types was made by their location in the different retinal layers. This was further assisted by our earlier reports on immunohistochemical studies of calcium binding proteins (Nag and Wadhwa 1996) and GABA (Nag and Wadhwa 1997) in the specific cell types in retinal sections from the same age groups. At 24–25 Wg, the pattern of GLU-IR was similar to that at 20–21 Wg, however, the notable change was the labelling of many more amacrine cells, some Müller cell

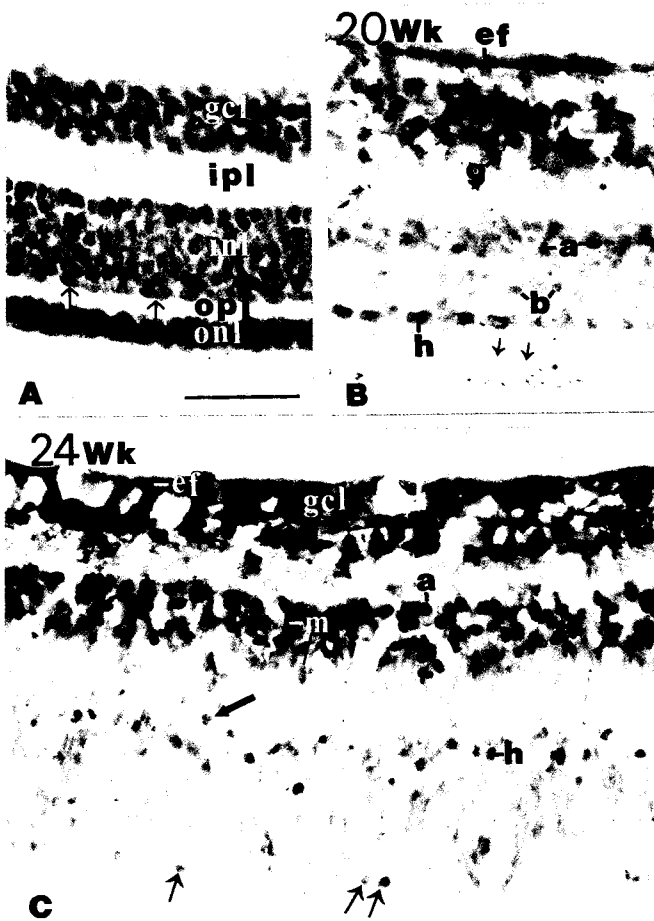


**Figure 1.** Glutamate immunoreactivity (IR) in the developing human retina. (A) At 14–15 Wg, intense IR is seen in the nerve fiber layer (nfl) of central retina. The arrow indicates a weakly-labelled ganglion cell. inz, inner neuroblastic zone; onz, outer neuroblastic zone. (B) At 17–18 Wg, in the midperipheral retina, the IR is seen in many cells (ganglion and displaced amacrine) lying in the ganglion cell layer (gcl). Note the faint IR in the prospective amacrine and photoreceptor cell bodies along the inner and scleral borders of onz respectively. ipl, inner plexiform layer; onz, outer neuroblastic zone. Scale bar = 50 µm.

elongated cell bodies and their endfeet and putative bipolar cells in central as well as in midperipheral (figure 2C) parts of the retina. Thus over the period of gestation studied, a gradient in development of GLU-IR from the central to peripheral retina and inner ganglion cell layer to outer photoreceptor layer was noted.

#### 4. Discussion

In the adult human retina, GLU is known to be present



**Figure 2.** (A) Part of central retina at 20–21 Wg, stained with H and E. The different layers and cell types are prominent at this stage. The arrows indicate horizontal cells. gcl, ganglion cell layer; ipl, inner plexiform layer; inl, inner nuclear layer; opl, outer plexiform layer; onl, outer nuclear layer. (B and C) Glutamate immunoreactivity (IR) in the developing human retina. At 20–21 Wg (B) central part of retina, showing IR in many ganglion cells (g) and Müller cell endfeet (ef), and occasional amacrine (a) and bipolar cells (b). The labelled horizontal cells (h) are aligned in a row. Photoreceptor cells (arrows) are weakly labelled. At 24–25 Wg (C) midperipheral part of retina shows many intensely labelled amacrine cells (a). Note the elongated perikarya of Müller cells (m) and their endfeet (ef) are clearly immunoreactive. The large arrow indicates a bipolar cell. The labelled photoreceptor cells are indicated by small arrows. h, horizontal cells; gcl, ganglion cell layer. Scale bar = 50 µm.

in the photoreceptors, bipolar and ganglion cells (Crooks and Kolb 1992). During development, depending upon the concentration of the neurotransmitter and the subtype of the receptor involved, glutamate has been shown to exert a variety of effects ranging from neuronal migration (Rakic *et al* 1994), neurite sprouting and maturation to neurotoxic effects of cell death (Lipton and Kater 1989) as well as synapse elimination (Rabbachi *et al* 1992). In the developing human retina, GLU appears additionally in the differentiating horizontal and amacrine cells. It turns out, therefore, that GLU occurs transiently in these neurons probably to subserve a developmental role. A similar situation has previously been reported in the developing rabbit retina (Redburn *et al* 1992). It is probable that GLU regulates growth and maturation of horizontal and amacrine cells in mammalian retinas. Since many of these neurons are GABAergic in fetal human retinas (Nag and Wadhwa 1997), it is logical to suggest that the GLU content therein many actually represent an endogenous pool (Redburn *et al* 1992), which acts as a precursor for GABA synthesis.

Expression of GLU in the bipolar cells of rabbit retina begins at 3–5 days after birth, coinciding with the earliest stages of their differentiation (Redburn *et al* 1992). In the human retina, the bipolar cells differentiate well before midgestation (20–21 weeks), as observed with synaptophysin labelling of their axonal terminals in the inner plexiform layer (unpublished observations). However, it is only from the age period of 20–21 weeks gestation that some early bipolar cells with low glutamate content become immunopositive in the human fetal retina.

An unexpected finding of this study was the glial localization of GLU, as observed in the developing Müller cells and their endfeet. To our knowledge, no reports have shown this in other species, including in the (adult) human retina. Glutamine, the main substrate for GLU synthesis is present in the Müller cells of rabbit retina (Pow and Robinson 1994), but not GLU, under normal conditions. The GLU content in these Müller cells is below the level of detection by immunohistochemistry, as was reported for the goldfish retina (Marc *et al* 1990). However, Haberecht and Redburn (1996) have determined biochemically that a large fraction of the endogenous glutamate pool is found extracellularly at postnatal day 1 in the rabbit retina, at which time the cones, horizontal cells and ganglion cells show glutamate immunocytochemically (Redburn *et al* 1992). Whether our observation with the fetal retina is due to a rapid postmortem redistribution of GLU to Müller cells (which thereby allowed its detection in these glia), or to a significant level of GLU present in the developing Müller cells of the human retina or to uptake from the extracellular glutamate pool remains to be answered.

The presence of a high level of glutamate in the ganglion cell layer of the developing human retina between 17

and 25 weeks of gestation is associated with a transient excess of nitric oxide synthase (NOS) in the ganglion cell layer during this period (unpublished observations). It is interesting to note that human retinal ganglion cell death (Provis et al 1985) and loss of optic nerve fibers (Provis et al 1985; Wadhwa and Bijlani 1987) occurs maximally during this period. It has been speculated that the NOS/nitric oxide/cGMP second messenger system may be involved in mediating glutamate-toxic death of ganglion cells (Huxlin and Bennett 1995; Nichol et al 1995) in addition to the other mechanisms involved in programmed developmental cell death (apoptosis).

### Acknowledgement

This study was supported by research grant to SW from the Council of Scientific and Industrial Research, New Delhi.

### References

- Barnstable C J 1993 Glutamate and GABA in retinal circuitry; *Curr. Opin. Neurobiol.* **3** 520–525
- Bodnarenko S R and Chalupa L M 1993 Stratification of ON and OFF ganglion cell dendrites depends on glutamate-mediated afferent activity in the developing retina; *Nature (London)* **364** 144–146
- Crooks J and Kolb H 1992 Localization of GABA, glycine, glutamate and tyrosine hydroxylase in the human retina; *J. Comp. Neurol.* **315** 287–302
- Haberecht M F and Redburn D A 1996 High levels of extracellular glutamate are present in retina during neonatal development; *Neurochem. Res.* **21** 285–291
- Hamilton W J, Boyd J D and Mossman, J W W 1962 *Human Embryology* 2nd edition (Cambridge: W Heffer)
- Hollenberg M J and Spira A W 1972 Early development of human retina; *Can. J. Ophthalmol.* **7** 472–491
- Huxlin K R and Bennett M R 1995 NADPH diaphorase expression in the rat retina after axotomy—A supportive role for nitric oxide?; *Eur. J. Neurosci.* **7** 2226–2239
- Lipton S A and Kater S B 1989 Neurotransmitter regulation of neuronal outgrowth, plasticity and survival; *Trends Neurosci.* **12** 265–270
- Mann I 1964 *The development of the human eye* 3rd edition (New York: Grune and Stratton)
- Marc R E, Liu W-L S, Kalloniatis M, Raiguel S F and Van Haesendonck E 1990 Pattern of glutamate immunoreactivity in the goldfish retina; *J. Neurosci.* **10** 4006–4034
- Massey S C 1990 Cell types using glutamate as a neurotransmitter in the vertebrate retina; *Prog. Retinal Res.* **9** 399–425
- McDonald J W and Johnston M V 1990 Physiological and patho-physiological roles of excitatory amino acids during central nervous system development; *Brain Res. Rev.* **1** 446–455
- Nag T C and Wadhwa S 1996 Calbindin and parvalbumin immunoreactivity in the developing and adult human retina; *Dev. Brain Res.* **93** 23–32
- Nag T C and Wadhwa S 1997 Expression of GABA in the fetal, postnatal and adult human retinas. An immunohistochemical study; *Vis. Neurosci.* **14** 425–432
- Nichol K A, Shutz M W and Bennett M R 1995 Nitric oxide mediated death of cultured neonatal retinal ganglion cells: neuroprotective properties of glutamate and chondroitin sulfate proteoglycan; *Brain Res.* **697** 1–16
- O'Rahilly R 1975 The prenatal development of the human eye; *Exp. Eye Res.* **21** 93–112
- Pow D V and Robinson S R 1994 Glutamate in some retinal neurons is derived solely from glia; *Neuroscience* **60** 355–366
- Pow D V, Crook D K and Wong R O L 1994 Early appearance and transient expression of putative amino acid neurotransmitters and related molecules in the developing rabbit retina: An immunocytochemical study; *Vis. Neurosci.* **11** 1115–1134
- Provis J M, van Driel D, Billson F A and Russel P 1985 Human fetal optic nerve: overproduction and elimination of retinal axons during development; *J. Comp. Neurol.* **238** 92–100
- Rabbachi S, Bailly Y, Delhaye-Bouchard N and Mariani J 1992 Involvement of NMDA receptor in synapse elimination during cerebellar development; *Science* **256** 1823–1825
- Rakic P, Cameron R S and Komuro H 1994 Recognition, adhesion, transmembrane signalling and cell motility in guided neuronal migration; *Curr. Opin. Neurobiol.* **4** 63–69
- Redburn D A, Agarwal S H, Messersmith E K and Mitchell C K 1992 Development of glutamate system in rabbit retina; *Neurochem. Res.* **17** 61–66
- Redburn D A and Rowe-Rendleman C 1996 Developmental neurotransmitters. Signals for shaping neuronal circuitry; *Invest. Ophthalmol. Vis. Sci.* **37** 1479–1482
- Rhodes R H 1979 A light microscopic study of the developing human neural retina; *Am. J. Anat.* **157** 195–210
- Wadhwa S and Bijlani V 1987 Developing human optic nerve in prenatal period: changes in the number of retinal axons; *Indian J. Ophthalmol.* **35** 11–16

MS received 24 October 1997; accepted 13 January 1998

Corresponding editor: M K CHANDRASHEKARAN