

Charcot Foot — An Update

PPK Gupta, V Mohan

INTRODUCTION

Charcot foot is a relatively uncommon complication of diabetes but one which can lead to chronic ulceration, marked deformity and amputation. Although its aetiology is not fully understood, several advances have occurred in its management. Surgery has a definite role to play but the mainstay of initial treatment is non-operative. Correct diagnosis can prevent progressive deformity. The timing and type of surgery are crucially important as inappropriate surgery may worsen the problem and lead to premature amputation.

INCIDENCE

Charcot foot or neuroarthropathy, is estimated to affect between 1-2.5% of people with diabetes.¹ It is most common in people with Type 1 diabetes in the fifth and sixth decade of life but can occur in young patients and in Type 2 diabetic patients as well. Usually, the duration of diabetes is greater than 12 years.² In most cases, it is unilateral but it may be bilateral in upto 25% of patients.³

In a study of about 20,000 consecutive diabetic patients, Bailey and Root⁴ reported 17 cases of Charcot's disease (prevalence 1:1100). However, many cases may have escaped recognition since the criterion for diagnosis was the presence of unilateral or bilateral thickening in the mid-foot. This is a late sign, indicative of significant joint destruction and bony fragmentation and adaptation. The most comprehensive study to date, conducted by Sinha⁵ found 101 cases of Charcot's disease among 68,000 consecutive diabetic patients (prevalence 1:680).

DEFINITION

Charcot foot can be defined as a relatively painless, progressive and degenerative arthropathy of single or multiple joints caused by an underlying neurological deficit. The amount of destruction and deformity seen clinically and on X ray can be quite considerable.

CAUSES

The association between a neurological deficit and an arthropathy was first suggested by Mitchell, an American physician, although it was Jean-Marie Charcot who famously

attached his name to this condition.⁶ Charcot observed the association between tabes dorsalis (due to syphilis) and arthropathy and even without the use of X rays, described the natural history of the condition. Although diabetes is today the main cause of Charcot joints in the developed world, other neuropathies can cause Charcot joints and in some countries leprosy may be the commonest cause. The causes of Charcot foot are summarized in Table 1.

Table 1. Reported causes of charcot foot

- | | |
|-----|--|
| 1. | Diabetes (major cause) |
| 2. | Leprosy (Hansen's disease) |
| 3. | Tabes dorsalis |
| 4. | Spinal cord tumor |
| 5. | Charcot Marie Tooth disease |
| 6. | Pernicious anaemia |
| 7. | Medications like steroids, phenylbutazone, indomethacin, vincristine |
| 8. | Alcoholism |
| 9. | Cerebral palsy |
| 10. | Hereditary insensitivity to pain |
| 11. | Myelodysplasia |
| 12. | Poliomyelitis |
| 13. | Syringomyelia |
| 14. | Tertiary syphilis |

ETIOLOGY

Two popular theories had been proposed to describe the cause of Charcot's disease.

I. French Theory

II. German Theory

The French theory⁶ espoused by Charcot postulated that a spinal cord lesion occurred that allowed trophic changes in the joints. This theory was based on the observation that changes in the joints were always preceded by sclerotic changes in the spinal cord.

The German theory described by Volkman and Virchow⁷ proposed that it was due to microtrauma, i.e., repeated unperceived subclinical trauma to insensitive joints. Loss of protective sensation allows abnormal mechanical stresses which would normally be prevented due to pain. This may then lead on to spontaneous fractures, subluxations and dislocations.

A vascular theory has recently been proposed.⁸⁻¹¹ Charcot's disease occurs most commonly in patients with palpable (often strongly so), pedal pulses. Also, several cases following lower extremity re-vascularization have been

MV Diabetes Specialities Centre and Madras Diabetes Research Foundation, Gopalapuram, Chennai, India.
Received : 14.10.2002; Accepted : 17.2.2002

described.¹¹ The presence of auto-sympathectomy leading to peripheral vasodilatation in diabetic patients with neuropathy is a well described phenomenon.¹² Edmonds et al¹³ further suggest that significant arteriovenous shunting takes place in the feet of neuropathic diabetic patients leading to abnormal bone cell activity and eventual resorption and weakening of the bone.

Autonomic neuropathy leads to increased blood flow with osteopenia thus weakening the bone and making it more susceptible to injury.¹⁴ However, Charcot foot may also occur following major trauma, such as fractured ankle and has been reported during bed rest.¹⁵ An adequate blood supply appears to be crucial as Charcot foot is not seen in ischaemic feet, but has been reported following successful revascularization.¹¹

ACUTE CHARCOT FOOT

The patient with an acute Charcot foot usually presents with a hot, swollen, erythematous foot which may be several degrees warmer than the contralateral foot and crepitus may be noted on manipulation of the foot. Typically, the patient may recall some minor trauma, perhaps weeks before. Sometimes there may be concomitant ulceration in the foot. Although the Charcot foot is often described as painless, patients will usually have some pain and discomfort. However, the level of pain reported by patients is normally considerably less than might be expected from the pathology seen.

Deformity may be evident at presentation. Depending on the timing of presentation, X rays may show no changes or healing fractures of the meta-tarsals or subluxation and dislocation of one or more joints. The most commonly affected site is the mid-foot (60% of patients) followed by the meta tarsophalangeal joints (30%) and the ankle joint (10%). Because of its mode of presentation, the acute charcot foot may be mistaken for infection with cellulitis and osteomyelitis. A useful clinical test is to adequately elevate the foot for five minutes. The erythema of a Charcot foot will recede, whereas that of a cellulitis foot will not.¹⁶

The results of nuclear medicine and magnetic resonance imaging scans must also be interpreted with caution as it is not easy to differentiate the acute Charcot foot from infection with osteomyelitis.¹⁶ That can lead to inappropriate surgery to deal with non-existent infection.

STAGES OF THE CHARCOT FOOT

The Charcot foot develops through three stages.¹⁷

Stage I : The Stage of Development, there is acute inflammation with hyperaemia, bone softening and

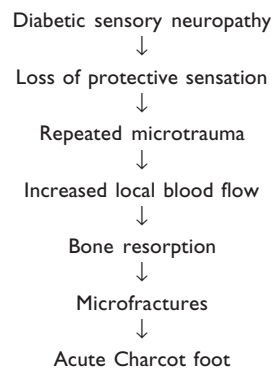


Figure 1. Schematic diagram showing development of Charcot foot.

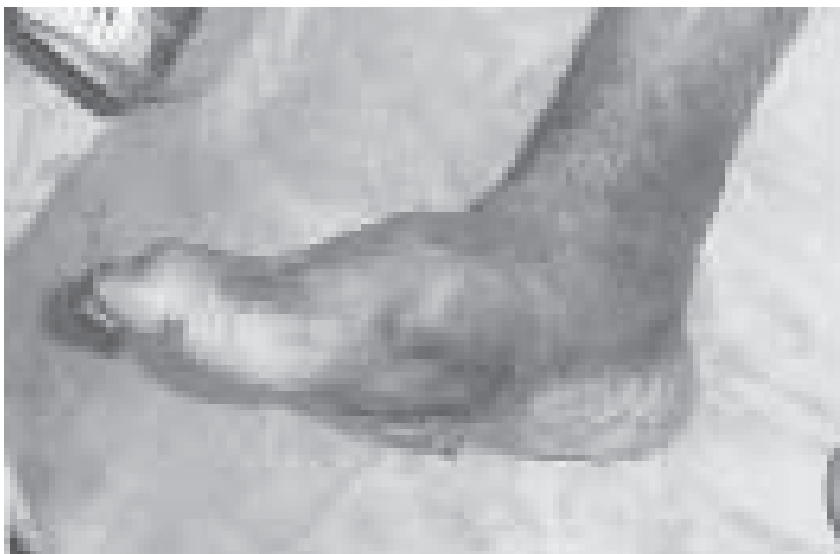

Fig 2a. Clinical appearance of Charcot's foot.

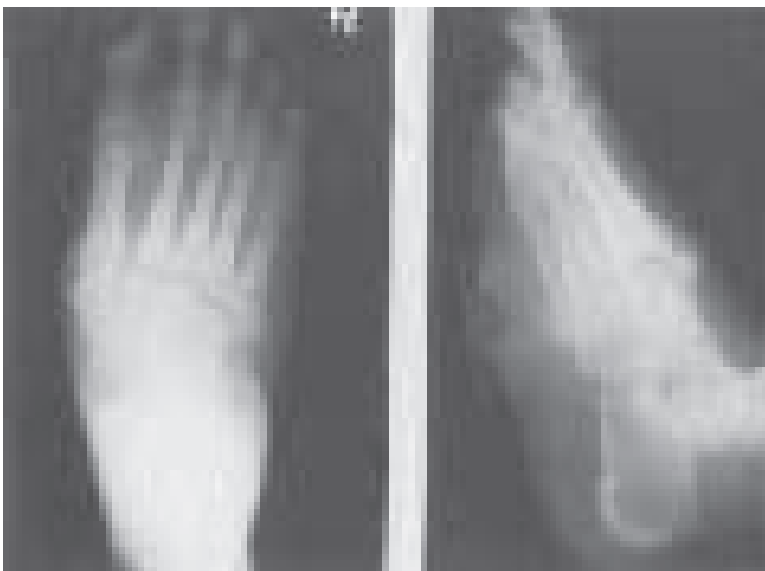

Fig 2b. Radiological appearance of same patient.

fragmentation and joint subluxation, dislocation and destruction. During this stage, the longitudinal arch of the foot may collapse, giving rise to a rocker bottom foot or mid

foot subluxation in the transverse plane which causes this typical deformity. Subluxation at the ankle joint may lead to marked varus and valgus deformity such that the patient is no longer walking on a plantigrade foot.

Stage II : The Stage of Coalescence, periosteal new bone formation is apparent along with reduction of swelling.

Stage III : The stage of Reconstruction, bony consolidation takes place and healing occurs.

Stage I represents the acute Charcot foot and Stages II and III, the reparative process. Progress through all the three stages, may take up to 2-3 years, although the acute phase may settle over a period of months.

RADIOLOGICAL CLASSIFICATION OF CHARCOT FOOT

Radiologically, Charcot's foot has been categorized as atrophic and proliferative types.

Atrophic Type : This type of disease is not commonly seen in the fore-foot. Marked osseous resorption of bone results in 'pencil pointing' or 'sucked candy' deformities of the metatarsal heads and shafts. These changes may be totally asymptomatic or may cause minimal signs and thus are only discovered accidentally on X-ray films.

Proliferative Type : This is the more common type and hence is more significant clinically. Proliferative or hypertrophic Charcot's disease affects the larger joints of the foot (i.e., mid-foot and rear foot) and there is destruction of bone followed by new bone formation.

INVESTIGATIONS IN CHARCOT FOOT

The diagnosis of Charcot foot remains primarily clinical, particularly in the early stages and the purpose of investigations is to distinguish Charcot foot from other conditions that cause pain and swelling of the foot such as osteomyelitis, inflammatory arthritis, cellulitis, trauma, deep vein thrombosis or gout.¹⁸

The investigations required for diagnosis of Charcot foot has been recently reviewed by Rajbhandari *et al.*¹⁹ The review suggests that even when the diagnosis is considered at an early stage, there are no definitive criteria or tests to confirm Charcot's neuroarthropathy and a high index of suspicion is necessary in any diabetic patient with a swollen warm foot in the presence of somatic or autonomic neuropathy.¹⁹

Plain X ray : The X ray of forefoot can show demineralization, bone destruction and periosteal reaction. Severe changes can develop in this form of Charcot foot with pencil and cup deformity at the metatarsophalangeal joints or fragmentation of the metatarsal heads.²⁰ In the midfoot, dislocation or fracture develops after initial joint swelling and ligamentous laxity.

Radionuclide (Isotope) Imaging : Radionuclide imaging can be a useful investigative tool in some instances. The three phase bone scan using technetium (TC-MDP) will be

positive in all three phases and merely reflects the increased turnover of bone in Charcot foot. It is very sensitive but not very specific. Labeled white cell scans (In-WBC) show increased activity at the site of infection but do not pick up new bone formation. Therefore, a combination of three phase TCMDP and In-WBC scans, which has a sensitivity and specificity of 80% to 90% is valuable for diagnosis if there is a penetrating ulcer underneath the deformity.²¹

Computerized Tomography (CT) and Magnetic Resonance (MR) Imaging : Computerized tomography scanning can detect the presence of sequestra, cortical destruction, periosteal reaction and intraosseous gas which might not be detected on MR imaging. However, magnetic resonance is superior for soft tissue imaging, gives exquisite anatomical detail²²⁻²⁵ and has largely superseded CT. Magnetic resonance scan of foot is extremely sensitive²⁶ having a 100% detection of abnormalities and thus the most sensitive modality discussed so far.

TREATMENT

Conservation Line of Management

The mainstay of therapy for acute Charcot's disease of the midfoot and rearfoot is immobilization, i.e., total prohibition from placing weight on the affected foot. Treatment of Charcot foot is aimed at reducing the swelling, minimising residual deformity and thus reducing the risk of neuropathic foot ulceration. Some centres will aim to reduce the swelling and mechanical stress by means of bed rest, elevation and non-weight bearing with crutches or a wheelchair. The disadvantage of this is that the acute phase may last for six months or so and patients with neuropathy and loss of sensation may not be compliant with this. Prolonged non-weight bearing may increase osteoporosis and further weaken the bone.

Use of either the total contact cast,²⁷ which is an excellent means of reducing swelling or the diabetic aircast walker with inflatable air cells, which some patients can tolerate better over a prolonged period of time. A total contact insole can be made for the walker. The aim of the total contact cast is to both reduce swelling and try to hold the shape of the foot while the bone is soft and deformable.

In recent years there has also been interest in the use of drugs designed to reduce bone turnover, by inhibiting osteoclastic activity as means of helping to settle the acute Charcot foot.²⁸ It is shown that intravenous bisphosphonate rapidly reverses the paradoxical increase in blood flow by antagonizing inflammatory mediators that increase blood flow and bone resorption in Charcot neuroarthropathy. Bisphosphonates have also been reported to improve pain and heat in the Charcot foot.²⁹

Surgical Management

In the acute stage I of the Charcot foot, surgery is almost totally contraindicated.³⁰ Metal work will not hold in soft fragmenting bone and the literature refers to many poor results from attempted arthrodesis.⁵ The exception to this

may be the acute unstable but manually reducible dislocation. Under this circumstances, success has been reported in obtaining stable reduction.³¹ However, any bony fragmentation or periosteal new bone formation is a contraindication.

Once the Charcot foot has reached a quiescent stage the patient is usually left with a neuropathic, deformed foot which is liable to recurrent ulceration over the bony prominences. Again, initial treatment will tend to be orthotic with footwear and insoles. However, recurrent ulceration in the presence of a fixed deformity will be an indication for surgery. Under these circumstances, surgery is indicated either to remove the bony prominences or correct deformities to produce a plantigrade foot which can be managed with orthotics. A further indication for surgery may be deep infection with abscess formation or osteomyelitis which may necessitate drainage or removal of infected bone. In one series, 50% of patients required surgery, including 21 major limb amputations.³²

Exostectomy

Removal of bony prominences is perhaps most common the 'Rocker Bottom Foot', where patients develops a plantar mid-foot prominence which is liable to recurrent breakdown. Before any surgery, it may be preferable to heal the ulceration, if practical, in order to minimize infection risk. It is also important to establish that there is no underlying osteomyelitis within the bony prominence.

Diagnosing osteomyelitis in the Charcot foot is not straight forward because of the already abnormal bony architecture. It may be necessary to do a bone scan in conjunction with an indium white cell labeled scan. If osteomyelitis is present, then a wider excision of bone may be indicated.

A midfoot plantar exostosis can be excised through an incision along the medial or lateral border of the foot. The soft tissues are stripped off the underlying bone and then either an oscillating saw or osteotome is used to remove the prominence and flatten the bony surface. The greater the surface area supporting weight, the less there will be of point loading with high peak pressures. A drain is normally used to reduce postoperative haematoma. Postoperatively, the wound is allowed to settle and weight bearing can then be commenced with or without a cast depending on whether any ulceration is still present.

Arthrodesis

Arthrodesis is usually reserved for midfoot and hindfoot deformities that are unbraceable and causing recurrent ulceration. This is a considerably more complex surgery that carries the risk of amputation if it is unsuccessful. In many cases however it can avoid the need for amputation and the significantly higher energy requirements of walking with an artificial leg. Once a person with diabetes has had one leg amputated, there is a high incidence of contralateral amputation within a few years.³³

CLASSIFICATION OF DEFORMITIES

A number of different classifications have been proposed for the different patterns of involvement in Charcot foot. Brodsky *et al*³⁴ suggested an anatomical classification into three main groups as follows:

1. Type 1 involving the tarsometatarsal and naviculocuneiform joints
2. Type 2 involving the subtalar complex including the talonavicular and calcaneocuboid joints.
3. Type 3A involving the tibiotalar joint and Type 3 B involving the posterior process of the calcaneum, which may develop a neuropathic fracture.

In Type 1 and 2, arthrodesis, rather than exostectomy, may be indicated where midfoot deformities are unstable and the Achilles tendon is tight, which exacerbates the rocker deformity. Realignment involves open reduction of the deformity and often, extensive fixation with interfragmentary screws. If the bone is too soft for solid fixation with screws, the fragments may be held with pins. Lengthening of the Achilles tendon may also be necessary.

Type 3 ankle involvement may cause marked malalignment in the coronal plane. Arthrodesis of the of the ankle joint can be accomplished in a standard manner with screw fixation if the hold on the bone is sufficiently good. If the bone is soft or a tibiocalcaneal arthrodesis is necessary, then an external fixator, such as the calandruccio clamp can be used or an intramedullary nail driven up through the heel. If an intramedullary nail is used then both the ankle and subtalar joints will be fixed.

Post-operative management may involve lengthy periods in plaster while bony union is taking place. Although some series have achieved good rates of union, solid bony union does not always occur. A number of these patients will stabilize through with a fibrous ankylosis and the deformity will be corrected sufficiently to adequately brace the foot and avoid recurrent ulceration. Nevertheless, this is not easy surgery and most series have significant complication rates. Twenty complications in 19 patients were reported in a series of 29 patients with neuro arthropathy.³⁵ Ten of the 29 patients had a pseudoarthrosis although seven of these were stable. One patient required a below knee amputation. However, all of these deformities were severe and amputation would have been an alternative to arthrodesis.

COMPLICATIONS

Almost all complications related to Charcot's foot are the result of distortion of the normal bony architecture of the foot. The most common deformity resulting from Charcot's disease of the mid foot is the Rocker Bottom Foot, caused by overloading of the medial aspect of plantar prominent bones. A less common but far more troublesome complication is Inversion Deformity resulting from excessive weight and pressure at the base of the fifth metatarsal and cuboid bones. This deformity is very difficult to control

with conservative means alone. Late diagnosis or patient non-compliance may result in significant bony deformities. Severe deformities causing bony prominences may result in areas of excessive pressure and chronic ulceration. Besides limiting the patient's activity, these ulcerations may result in infection and possibly osteomyelitis.

Although some residual deformity (chronic swelling) will always remain in patients who have had severe Charcot's disease, significant and troublesome skeletal deformities can be avoided with prompt treatment.

SPECIAL FOOTWEAR

An active Charcot foot should be immobilized in a plaster cast until the condition has stabilized (cooled-off) and the required footwear is ready.³⁶ A cooled-off Charcot foot requires a shoe that prevents further collapse of the foot which is similar to a plaster case.^{37,38} In other words, it requires a high, stiffened shoe that has a full contact insole and a rocker bottom sole with an early pivot point and shock absorption through the heel.

CONCLUSIONS

Although Charcot's disease and its association with diabetes have been described many times in the literature, it is still often misdiagnosed and incorrectly treated as osteomyelitis, arthritis or gout. The best safeguard is a high index of suspicion. A warm swollen foot in a diabetic patient with long standing neuropathy without local or systemic signs of infection must be considered Charcot's foot until proven otherwise. The principle treatment is total abstinence from putting weight on the foot until warmth, swelling and redness subside. Protective weight bearing methods may then be slowly instituted.


The Charcot foot represents a formidable clinical challenge. There is much that is still not understood about it, but indications for surgery and techniques of stabilizing the foot have advanced considerably over the last decade. Perhaps, better control of diabetes and improved treatment of neuropathy may help to prevent this potentially crippling disorder.

REFERENCES

1. Myerson MS. Salvage of diabetic neuropathy arthropathy with arthrodesis. In: Helal B, Rowley D, Cracchiolo A, Myerson M, eds. *Surgery of disorders of the foot and ankle*. Martin Dunitz, London, 1996:513-22.
2. Laing PW. The foot in diabetes. In: Klenerman L, ed. *The foot and its disorders*. Blackwell Scientific, London, 1991:139-52.
3. Frykberg RG. Charcot foot. In: Boulton AJM, Connor H, Cavanagh PR, eds. *The foot in diabetes*. John Wiley Sons, Chichester, 2000:235-60.
4. Bailey CC, Root HP. Neuropathic foot lesions in diabetes mellitus. *N Eng J Med* 1947;236:397-401.
5. Sinha SB, Munichoodappa CS, Kozak GP. Neuro arthropathy (Charcot joints) in diabetes mellitus: Clinical study of 101 cases. *Medicine (Baltimore)* 1972; 51:191-210.
6. Charcot JM. Sur quelques arthropathies quiparaissent dependre d'une lesion du cerneau dela moelle epiniere. *Arch Des Physiol Normet Path* 1868;1:161.
7. Delano PJ. The pathogenesis of Charcot's joint. *Am J Roentgenol* 1946;56:189-200.
8. Edmonds ME, Roberts VC, Watkins PJ. Blood flow in the diabetic neuropathic foot. *Diabetologia* 1982;22:9-15.
9. Scarpello JH, Martin TR, Ward JD. Ultrasound measurements of pulse wave velocity in the peripheral arteries of diabetic subjects. *Clin Sci* 1980;58:53-57.
10. Boulton AJ, Scarpello JH, Ward JD. Venous oxygenation in the diabetic neuropathic foot: evidence of arteriovenous shunting. *Diabetologia* 1982;22:6-8.
11. Edelman SV, Kosofsky EM, Paul RA, et al. Neuro osteo arthropathy (Charcot's joint) in diabetes mellitus following revascularization surgery: three case reports and a review of the literature. *Arch Intern Med* 1987;147:1504-8.
12. Friedman SA, Rakow RB. Osseous lesions of the foot in diabetic neuropathy. *Diabetes* 1971;20:302-7.
13. Edmonds ME, Clarke MB, Newton S, et al. Increased uptake of bone radiopharmaceutical in diabetic neuropathy. *Q J Med* 1985;57:843-55.
14. Brooks AP. The neuropathic foot in diabetes. Part II: Charcot's neuroarthropathy. *Diabetic Medicine* 1986;3:116-8.
15. Brower AC, Allman RM. Pathogenesis of the neurotrophic joint: neurotraumatic vs neurovascular. *Radiology* 1981;139:349-54.
16. Brodsky JW. The diabetic foot. In: Mann RA Coughlin MJ, eds. *Surgery of the foot and ankle*. Mosby, St. Louis. 1993:877-958.
17. Eichenholtz SN. Charcot joints. In: Charles C. Thomas, Springfield, Illinois. *The Diabetic Foot* 2000;3:46.
18. Wilson M. Charcot foot osteoarthropathy in diabetes mellitus. *Mil Med* 1991;156:563-9.
19. Rajbhandari SM, Jenkins RC, Davies C, Tesfaye S. Charcot neuroarthropathy in diabetes mellitus. *Diabetologia* 2002;45:1085-96.
20. Gold RHM, Tong MD, Crim JR, Seeger LL. Imaging the diabetic foot. *Skeletal Radiol* 1995; 24:563-71.
21. Tomas MB, Patel M, Marvin SE, Palestro CJ. The diabetic foot. *Br J Radiol* 2000;73:443-50.
22. Lipman BT, Collier BD, Carrera GF, et al. Detection of osteomyelitis in the neuropathic foot: nuclear medicine, MRI and conventional radiography. *Clin Nucl Med* 1988;23:77-82.
23. Palestro CJ, Mehta HH, Patel M, et al. Marrow versus infection in charcot joint: Indium-111 leukocyte and technetium - 99m sulphur colloid scintigraphy. *J Nucl Med* 1998;39:346-50.
24. Sartosir DJ. Cross-sectional imaging of the diabetic foot. *J Foot Ankle Surg* 1994;33:531-45.
25. Deely DM, Schweitzer ME. MR imaging of bone marrow disorders. *Radiol Clin North Am* 1997;35:193-212.
26. Myerson MS, Alvarez RG, Lam PW. Tibiocalcaneal arthrosclerosis for the management of severe ankle and hind foot deformities. *Foot Ankle Int* 2000;21:643-50.
27. Laing PW, Cogley DI, Klenerman L. Neuropathic foot ulceration treated by total contact casts. *J Bone Joint Surg* 1992;74-B:133-36.

28. Selby PL, Young MT, Boulton AJM. Bisphosphonates: a new treatment for diabetic charcot neuro arthropathy? *Diabetic Medicine* 1994;11:28-31.
29. Stansberry KB, Moss QE, Peppard HR, et al. Intravenous bisphosphonate rapidly reverses the paradoxical increase in blood flow to the foot in charcot neuroarthropathy. *Diabetes* 1998;48 (suppl 1):A-92, 395.
30. Laing P. Surgical management of the Charcot foot. *The Diabetic Foot* 2000; 3:44-48.
31. Myerson MS, Henderson MR, Saxby T, et al. Management of mid foot diabetic neuro arthropathy. *Foot and Ankle International* 1994;15:233-41.
32. Pinzur MS. Benchmark analysis of diabetic patients with neuropathic (Charcot) foot deformity. *Foot and Ankle International* 1999;20:564-7.
33. Spencer F, Sage R, Graner J. The incidence of foot pathology in a diabetic population. *J Am Pod Med Association* 1985;75:590-2.
34. Brodsky JW, Kwong PK, Wagner FW, et al. Patterns of breakdown, natural history and treatment of the diabetic charcot tarsus. *Orthopaedic Transactions* 1987;11:484.
35. Papa J, Myerson M, Girard P. Salvage with arthrodesis in intractable diabetic neuropathic arthropathy of the foot and ankle. *J Bone Joint Surg* 1993;75A:1056-66.
36. Armstrong DG, Todd WF, Lavery LA, et al. The natural history of acute Charcot's arthropathy in a diabetic foot speciality clinic. *Diabetic Medicine* 1997;14:357-63.
37. International Working Group on the Diabetic Foot. International consensus on the diabetic foot. Amsterdam. The International Working Group on the Diabetic Foot. *Diabetes Care* 2001;24:706.
38. Janisse D. Prescription insoles and footwear. *Clin Pod Med Surg* 1995;12:41-61.

Announcement



The following members were awarded the Fellowship of ICP at Varanasi APICON 2003

- | | |
|---|--|
| 1. Dr. Sanjay K Agarwal, New Delhi | 17. Dr. Narendra Singh Negi, New Delhi |
| 2. Dr. MA Aleem, Trichy | 18. Dr. NS Neki, Amritsar |
| 3. Dr. Manas Kumar Banerjee, Asansol | 19. Dr. Krishna Kumar Pareek, Kota |
| 4. Dr. Anil Bharani, Indore | 20. Dr. Falguni S Parikh, Mumbai |
| 5. Dr. Anant Kumar Gupta, Ajmer | 21. Dr. Keechilat Pavithran, Trivandrum |
| 6. Dr. Arvind Gupta, Jaipur | 22. Dr. Prabal Rajvanshi, New Delhi |
| 7. Dr. Rakesh Gupta, New Delhi | 23. Dr. Bharat Bhushan Rewari, New Delhi |
| 8. Dr. Niwruiti Khandu Hase, Mumbai | 24. Dr. Ranjan Sankar, Delhi |
| 9. Dr. Vasantha Kamath, Bangalore | 25. Dr. Shiv Kumar Sarin, New Delhi |
| 10. Dr. Ghulam Qadir Khan, Srinagar | 26. Dr. BD Sharma, Delhi |
| 11. Dr. Kailash Kumar, Varanasi | 27. Dr. Rajendra Pratap Singh, New delhi |
| 12. Dr. Suresh Meratwal, Ajmer | 28. Dr. Rana Gopal Singh, Varanasi |
| 13. Dr. Sri Prakash Misra, Allahabad | 29. Dr. Surendra Kumar Verma, Udaipur |
| 14. Dr. Dindagnur Nagaraja, Bangalore | 30. Dr. IB Vijayalakshmi, Bangalore |
| 15. Lt. Col. (Dr.) Velu Nair, New Delhi | 31. Dr. Sunil Wadhwa, New Delhi |
| 16. Dr. Gumdal Narsimlu, Hyderabad | 32. Dr. Pushpa Yadav, Delhi |

S d / -

Dr. Sandhya Kamath
Hon. General Secretary