

# Assessment of the therapeutic response of human breast carcinoma using *in vivo* volume localized proton magnetic resonance spectroscopy

N. R. Jagannathan\*\*, Mahesh Kumar, P. Raghunathan, O. Coshic\*,  
P. K. Julka<sup>†</sup> and G. K. Rath<sup>†</sup>

Department of N.M.R., \*Department of Surgery and <sup>†</sup>Department of Radiotherapy, All India Institute of Medical Sciences, Ansari Nagar, New Delhi 110 029, India

Breast cancer is the commonest cancer among females and is a significant cause of morbidity and mortality. Diagnostic techniques are becoming mandatory for early diagnosis, treatment and improved survival. Screening procedures such as clinical breast examination, ultrasound, and mammography are often limited in sensitivity and specificity. Magnetic resonance imaging (MRI) is a new noninvasive valuable tool for doing diagnostic mammography and combined with *in vivo* magnetic resonance spectroscopy (MRS), it offers an attractive alternative to monitor tissue biochemical/metabolic changes. In this brief review, we discuss the potential of noninvasively monitoring and assessing the response of breast cancer to neoadjuvant chemotherapy using *in vivo* volume localized proton MRS method that is employed in our laboratory.

BREAST cancer is the second most common cancer among women in India after cervical cancer and is likely to emerge as the major malignant neoplasm among female patients in the future, constituting a major health problem<sup>1,2</sup>. In Mumbai, about 1 in 35 women have a lifetime risk of breast cancer. According to the WHO, worldwide deaths due to breast cancer will rise to 500,000 by the year 2000, and almost a fifth of those will be from the Indian subcontinent. Hence, early detection of cancer is the primary strategy for reducing the mortality<sup>3</sup>. In recent years, several screening procedures are being followed such as clinical breast examination, ultrasound, and mammography and these are often limited in sensitivity and specificity<sup>4,5</sup>. Physical examination has limitations due to individual variation in breast parenchymal consistency, the location, the size and the presence of a diffuse versus discrete tumour. Approximately, 5–15% of the palpable breast cancers are not detected in conventional mammography examination<sup>6–8</sup>. There are additional 'subclinical' cancers that are found only in histopathologic analysis. In view of these limita-

tions of mammography and other techniques, considerable interest is now being focused on breast MRI<sup>9</sup>. Different MRI methodologies were explored in the past in order to improve the detection and diagnosis of breast diseases<sup>10–17</sup>. The sensitivity and specificity of MRI for the detection of breast cancer can be significantly increased by the use of paramagnetic contrast media such as gadolinium diethylenetriaminopentaacetic acid (Gd-DTPA). Recently, dynamic contrast MRI techniques have also been developed for differentiation of benign from malignant tumours<sup>13,17</sup>. Tumour size measured using MR images correlates well with the size of pathological tumours<sup>18</sup>. This is useful in assessing the response of the tumour to neoadjuvant chemotherapy, where it has been seen that clinical examination, ultrasound, and mammography do not always correlate with the pathological response<sup>18</sup>.

In spite of the wealth of information obtained using the above techniques, they do not provide cellular biochemical information about the cancer/tumour or its response to therapy. *In vivo* MRS is a technique that provides noninvasive detection of metabolites and has been successfully applied to monitor tumour development, progression, and response to different treatment regimens<sup>19–21</sup>. *In vitro* and breast cell line studies have shown that malignant breast tumours have elevated phosphocholine (PC) compared to normal breast tissue<sup>22–25</sup>. Using surface coil proton MRS, it has been reported that water-to-fat (W/F) ratio was high in breast cancer patients compared to normal volunteers<sup>26</sup>. It is known, that contamination from signals of non-tumour regions is likely to arise due to poor selectivity of the region of interest (ROI) when the surface coil method is used. For example, in <sup>31</sup>P MRS of breast carcinoma the appearance of PCr resonance may be due to the involvement of the chest wall<sup>27,28</sup>. Such observations emphasize the importance of careful localized volume selection procedures for studying breast tumours<sup>29</sup>.

In general, the response to neoadjuvant chemotherapy for locally advanced breast cancer is assessed by measurement of the reduction in the tumour size by clinical

\*\*For correspondence. (e-mail: nrj@medinst.ernet.in)



examination and/or by ultrasound or mammography. Recently, MRI has been found to be more accurate than clinical examination, ultrasound or mammography used either in isolation or in combination<sup>18</sup>. However, the histological correlation of response with all the presently used modalities is not satisfactory. Sometimes the lump persists while the histological examination reveals only a necrotic or fibrotic residue. Conversely, it is often seen that a complete clinical and even radiological response still shows residual tumour on histological examination. Therein lies the potential value of the MRS technique in helping to quantify more accurately the response of breast cancer to neoadjuvant chemotherapy, which is an issue of considerable clinical significance. Recently, we have shown the feasibility of carrying out localized *in vivo* proton MRS in a group of breast cancer patients<sup>30</sup>.

The focus of this review is to assess the sensitivity and specificity of *in vivo* proton MRS in patients suffering from infiltrating duct carcinoma of breast, carried out in our laboratory. Accordingly, details of the experimental protocol employed by us as well as the criteria adopted in selecting the patients are discussed in the following sections. Data obtained from our study on 64 patients ( $n = 64$ ) are presented next and the potential of non-invasively monitoring and assessing the response of breast cancer to neoadjuvant chemotherapy is discussed in the last section of this article.

### MRI and *in vivo* proton MRS measurements

MRI and MRS were performed at 1.5 Tesla (MAGNETOM, Siemens) using a bilateral surface receiver coil (single, linearly polarized, elliptically shaped and breast-contour fitted) for optimal signal reception with the body coil acting as a transmitter. Automatic tuning and electronic decoupling ensured optimization of signal reception. Each subject was positioned prone with each breast fitting into a cup of the surface receiver coil. Following the scout image,  $T_1$ -weighted MRI in the sagittal plane were obtained using a spin echo sequence. To identify precisely the full extent of the irregular, spiculated border of malignant tumours, fat suppressed proton MRI in the axial and coronal planes were recorded. Depending on the tumour size, voxels of appropriate dimension (nominally 1 to 8 ml) were chosen and positioned well within the tumour area for further MRS study.

Volume localized *in vivo* proton MRS was carried out using the STEAM pulse sequence<sup>31</sup>. Magnetic field shimming was done both globally and over the voxel region prior to MRS studies. The line-width after voxel shimming corresponded typically to 10–16 Hz for the lipid peak in case of normal/control breast and 5–10 Hz for the water peak in patients with breast tumours. 32 to

64 scans with and without water suppression were collected using an echo time (TE) of 135 ms and a repetition time (TR) of 3 s. The free induction decays were zero filled to 4 K data points with a gaussian broadening of 4 Hz before Fourier transformation. Chemical shifts are reported using water as the internal standard at 4.70 ppm. The total study time per patient was around 60 to 75 min including imaging and spectroscopy. In all cases, the water-fat (major fat peak, *vide infra*) ratio was calculated using the respective peak areas. Furthermore, random checks were made by positioning the voxel in different locations within the tumour site; the lack of any variability in the W/F ratio beyond the experimental error (which is around 10%) ensured that the region chosen was not heterogeneous.

For *in vitro* NMR measurements, human breast tumour specimens were collected from five patients who were undergoing scheduled surgical procedures. Proton NMR spectra at 400 MHz (Bruker, DRX-400) of the perchloric acid extract of the specimen was recorded at a pH of 7.8 at 25°C.

All data are reported as mean  $\pm$  SEM. Statistical significances between different groups were determined through ANOVA test. A level of  $P < 0.05$  was accepted as statistically significant.

### Patients and controls

A total of 64 women (both pre- and post-menopausal), of average age  $46.1 \pm 10.3$  years, all suffering from infiltrating duct carcinoma, were selected for this study. Tumour staging and size were evaluated clinically by TNM (tumour, nodes, metastasis) procedure. In all the cases, the tumour size was  $> 2$  cm with or without skin involvement. All patients had histological or cytological confirmation of infiltrating duct carcinoma, and no other histology was detected. Most patients ( $n = 44$ ) received CAF (cyclophosphamide + adriamycin + 5-FU) chemotherapy while a few of them received either CMF ( $n = 10$ , cyclophosphamide + methotrexate + 5-FU) or Paclitaxel<sup>R</sup> + Epirubicin<sup>R</sup> ( $n = 10$ ). One 'cycle' corresponded to two injections of the drug with an interval of one week. None of the patients was on prior hormone treatment, and none of them had used contraceptive pills. For 29 patients chosen out of the overall patient pool, proton MR spectra from the unaffected contralateral breast were also recorded. In addition, 15 normals (volunteers,  $n = 15$ ) of nearly the same age group were recruited as controls. Written informed consent was obtained before examination from patients and controls.

To facilitate the experimental protocol and statistical analysis (*vide infra*), the subjects studied have been classified as follows: normals (control,  $n = 15$ ); from overall patient pool: Group 1 (pre-therapy,  $n = 33$ ), group 2 (after 1–2 cycles of chemotherapy,  $n = 11$ ),



group 3 (after 3–4 therapeutic cycles,  $n = 18$ ), and group 4 (completion of full course of chemotherapy regimen,  $n = 15$ ). Seven cases from the overall patient pool were investigated three or four times each during successive chemotherapeutic stages: pre-therapy, and after second, fourth and sixth cycle of therapy.

## Results and discussion

Proton MR spectrum (without water suppression) from an 8 ml voxel of a normal breast tissue of a control (volunteer) and the corresponding voxel location in the MR image are shown in Figure 1 *b* and *a*. Resonances from lipid protons dominate the spectrum and the various assignments of the different metabolite peaks were carried out using literature data<sup>26</sup>. Accordingly, the major peak at 1.3 ppm was assigned to the methylene ( $-(CH_2)_n-$ ) protons of the lipids and the peak around 0.9 ppm, appearing as a shoulder to that at 1.3 ppm, is from the terminal methyl protons present in glycerides. The methylene protons  $\alpha$  to the carboxyl in the glyceride chain appear at 2.2 ppm, while the peak near 2.5 ppm is assigned to the diallylic  $CH_2$  protons of the lipid chain. The olefinic hydrogens and the CH of glycerol backbone appear near 5.2 ppm and the water peak is around 4.7 ppm. The proton MR spectrum shown in Figure 1 *b* is also typical of the spectra obtained from the contralateral unaffected breast of the patients ( $n = 29$ ).

The unsuppressed proton spectrum from an 8 ml voxel carefully positioned within the tumour region (see MR image, Figure 2 *a*) of a patient suffering from infiltrating duct carcinoma (histologically proven) is shown in Figure 2 *c*. Clearly, the spectrum is seen to be different from that obtained for the normal breast tissue, the water peak dominating with a much lower contribution from the protons of the fatty acid chains. In the controls

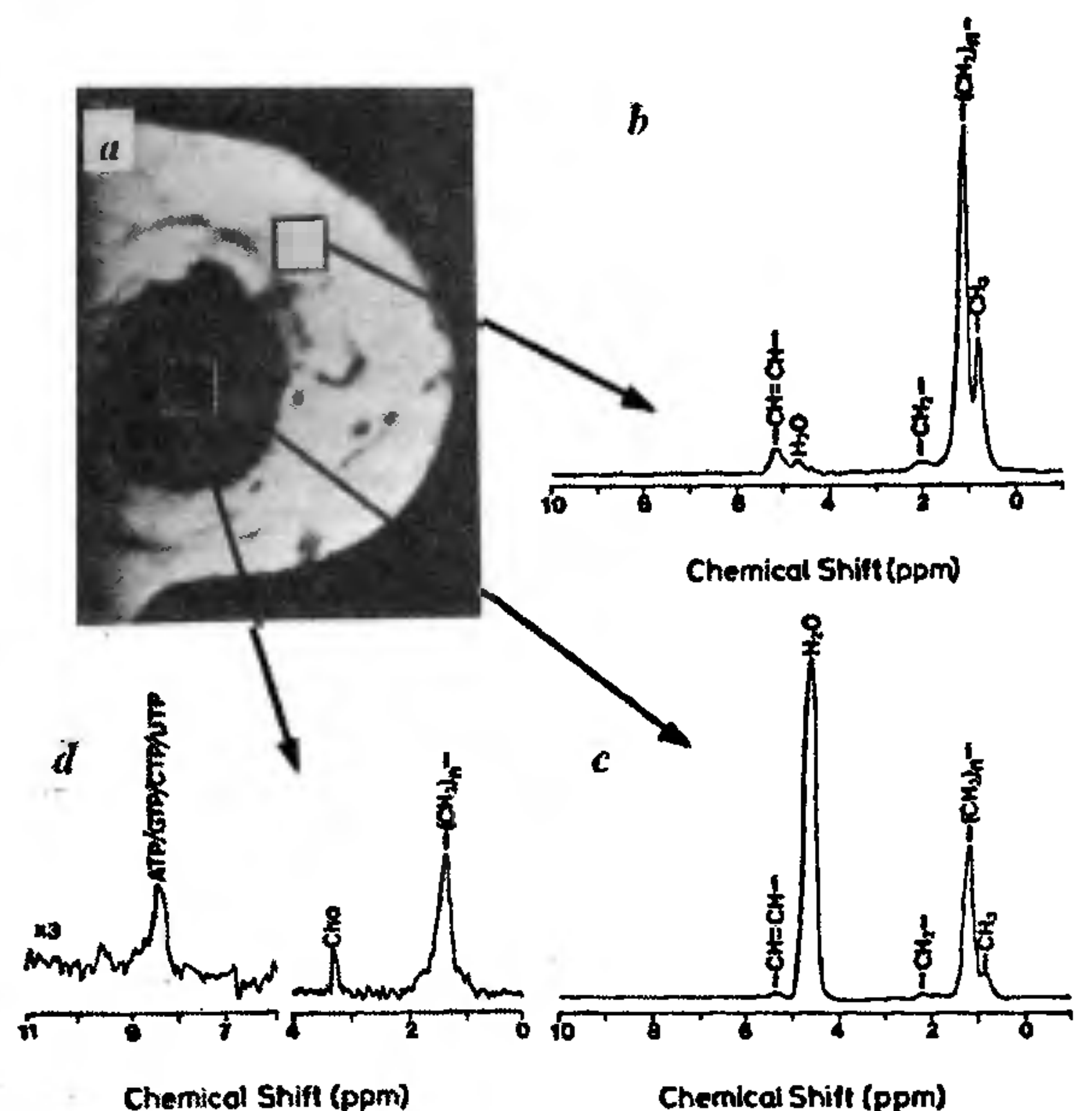


Figure 2 *a*,  $T_1$ -weighted sagittal MR image of a patient suffering from infiltrating duct carcinoma; *b*, Proton MR spectrum from an 8 ml voxel positioned in the normal portion of the affected breast; *c*, Proton spectrum from an 8 ml voxel positioned well within the tumour; *d*, The water suppressed spectrum showing the choline and other low concentration metabolites.

(volunteers), the ratio between the integrated areas of the water peak and the major fat peak (at 1.3 ppm) ranged from 0.1 to 0.8 with a mean of  $0.34 \pm 0.25$ . The W/F ratio from the unaffected contralateral breast, recorded from a representative sample population of the patients ( $n = 29$ ), also showed a similar value of  $0.35 \pm 0.42$ . Compared with the spectra of their normal counterparts, localized proton spectra of the tumours are characterized by high W/F values which vary from 1 to 30.

The W/F ratio calculated before and after therapy for all the patients studied, together with the data from controls and the results of statistical analysis are presented in Table 1. Pre-therapy W/F value of 3 patients were excluded in the final analysis since the W/F values were found to be within the normal range, in conformity with histological data. From the tabulated W/F values several interesting conclusions emerge. A statistically significant ( $P < 0.001$ ) reduction in the W/F ratio was noticed in patients who have undergone the full course of chemotherapy regimen ( $1.2 \pm 1.5$ ) compared to the pre-therapy value of  $7.2 \pm 7.4$ . This finding correlates well with the mammography and clinical examinations carried out on these patients after the completion of the full course of chemotherapy. For patients who had received 3 or 4 cycles of chemotherapy (group 3) the W/F value was around  $1.7 \pm 1.4$ , which is again a statistically significant reduction compared to the pre-therapy value.

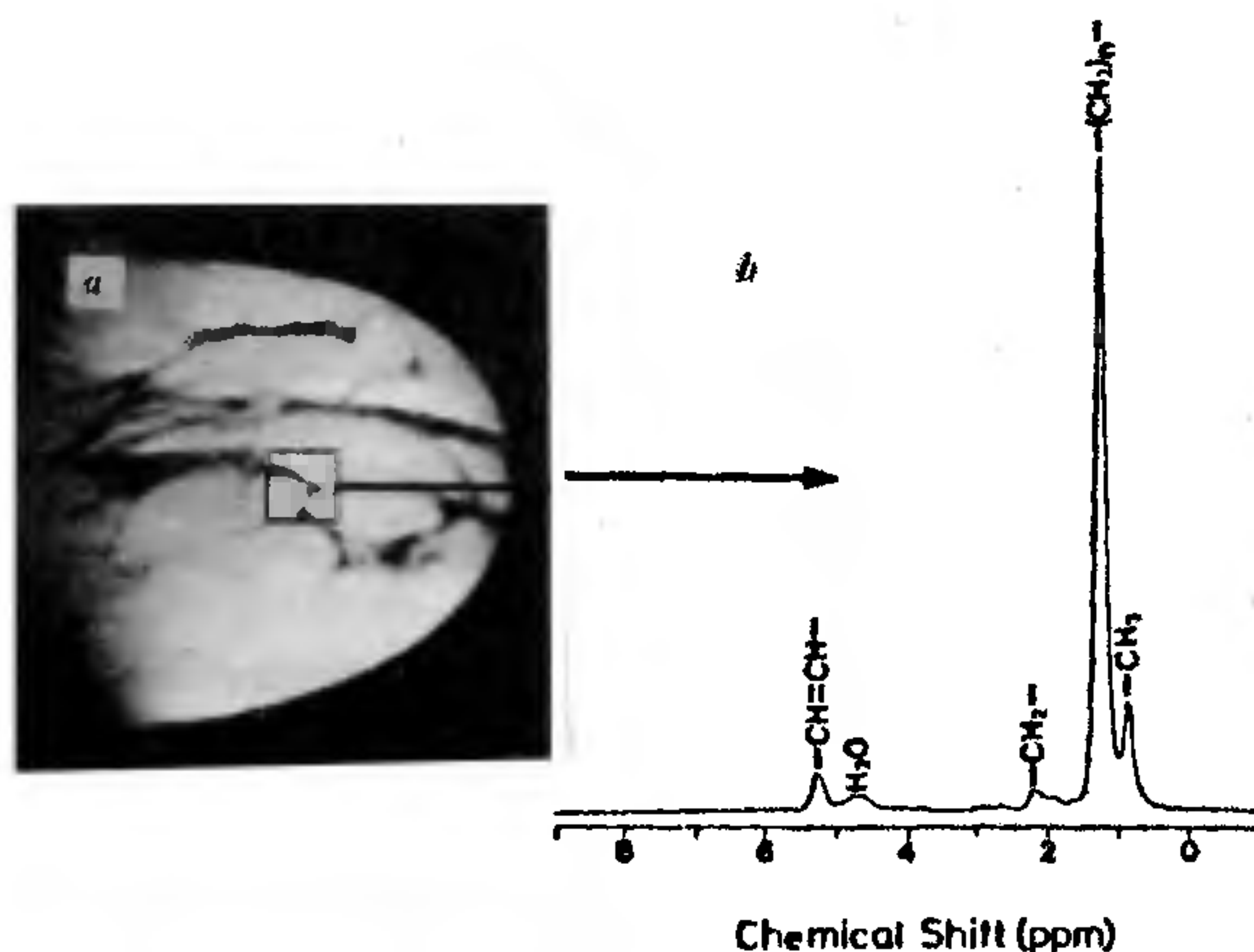


Figure 1. *In vivo* proton MR spectrum from an 8 ml voxel of a normal breast tissue from a volunteer.



Table 1. Water-to-fat ratios in normal volunteers and in infiltrating duct breast cancer patients

Control (n = 15)	Contralateral unaffected breast of patients (n = 29)	Pre-therapy group 1 (n = 33)	After 1-2 cycles of chemo group 2 (n = 11)	After 3-4 cycles of chemo group 3 (n = 18)	After 5-6 cycles of chemo group 4 (n = 15)	Voxel away from tumour (n = 31)
0.34 ± 0.25	0.35 ± 0.42	7.2 ± 7.4	5.8 ± 4.6	1.7 ± 1.4	1.2 ± 1.5	0.26 ± 0.31
	[P < 0.5 with control]	[P < 0.002 with control]	[P < 0.2 with pre-therapy]	[P < 0.001 with pre-therapy]	[P < 0.001 with pre-therapy]	[P < 0.00001 with pre-therapy]

Expectedly, during the early stages of the chemotherapy cycle (1-2 cycles), the W/F ratio varied over a wide range (2-15) and is also not significantly different from the pre-therapy W/F value (see Table 1). For 5 patients, a very high pre-therapy (W/F) value (> 70) was observed, which remained high (> 30) in two patients even after the full course of chemotherapy, while for the other three patients mastectomy was performed after the third cycle of chemotherapy. The high W/F value observed in these patients may reflect the presence of oedema which clinically correlates with the condition seen in patients with lymphatic blockage and involvement of sub-dermal lymphatics by tumour. In these patients, the high W/F content may be an indicator of the presence of 'peau d'orange'. In addition, the persistently high W/F ratio seen in two patients even after the full course of chemotherapy correlates well (clinically) with the incomplete response of the tumour to neoadjuvant chemotherapy.

The observation of elevated W/F values observed for breast cancer patients is in agreement with the generally established trend that tumours have considerably higher water content<sup>30,32,33</sup>. In addition, it is reported that mice tumours comprise 84% water by tissue weight, whereas fat accounts for only 12% (ref. 34). Mackinnon *et al.*<sup>35</sup> have recently reported that changes in lipid content also occur with tumour development and progression.

In order to evaluate the usefulness of W/F ratios as possible signatures of breast cancer, localized proton MR spectra were recorded for 29 patients from the overall pool (n = 29) choosing both tumour and non-tumour regions of the breast. Figure 2b shows the spectrum from a voxel which was slightly shifted away from the tumour site (Figure 2a) and the W/F value calculated is similar to that obtained from the controls (normal breast tissue) or from the contralateral unaffected breast tissue of the patients (see Table 1). Thus, it is clear that the W/F value from the malignant breast tissue is different (P < 0.0002) from that obtained from the normal portion of the breast. This simple exercise confirmed that the proton spectra obtained using volume localization method reflect truly the nature of the tissue state. It also suggests the possibility of using the W/F ratios for assessing the response of tumours to neoadjuvant chemotherapy. Experiments such as two-

dimensional or three-dimensional chemical shift imaging should greatly help in discriminating normal and diseased portions of the breast, as has been pointed out recently by using <sup>31</sup>P MRS<sup>36</sup>.

Figure 3 shows the plot of W/F as a function of chemotherapy cycle for 7 patients who were studied at different time periods. Clearly, the W/F ratio which was higher prior to therapy showed a lower value after the completion of the full course of the treatment. Mammography and clinical examinations carried out on these patients after the completion of the therapy confirmed our MRS finding. For patient no. 16, the W/F ratio was higher even after the full course of the treatment. Clinical, mammography, and MRI investigations showed no substantial reduction in the tumour size, confirming our MRS data. Patient no. 43 and no. 47 were operated after the 3rd cycle of treatment.

The water suppressed proton MR spectrum from an 8 ml voxel positioned in the tumour of a patient is shown in Figure 2d. In addition to the residual fat and water, a choline peak at 3.2 ppm and other minor resonances in the 8 to 9.5 ppm range are clearly seen. Assignment of these peaks was made with the help of literature data<sup>22,23,37</sup> as well as from the *in vitro* proton one-dimensional and two-dimensional NMR spectra recorded at 400 MHz on the perchloric acid extract of the breast tumour tissues (n = 5; spectra not shown). Accordingly, the resonances around 8.5 ppm are assigned to the protons of purine (ATP and GTP) and pyrimidine (uridine and cytidine phosphates) nucleotides. Such resonances were also detected in PCA extracts of other tumour tissues<sup>38</sup>. The origin of the resonance peak around 9.5 ppm is not clear. However, Gribbestad *et al.*<sup>22,23</sup> from *in vitro* NMR study have assigned these resonances to protons from NAD (nicotine adenine nucleotide).

Absence of choline in benign breast tumours has been recently reported from *in vitro* NMR studies of FNAB samples<sup>35</sup>. The phosphocholine (PC) and phosphoethanolamine (PE) pools in the tissue have two main sources. These are precursors in the synthesis of phosphatidylcholine (PCho) and phosphatidylethanolamine (PEth), respectively, and are also degradation products of phospholipid breakdown by phospholipase C. Several



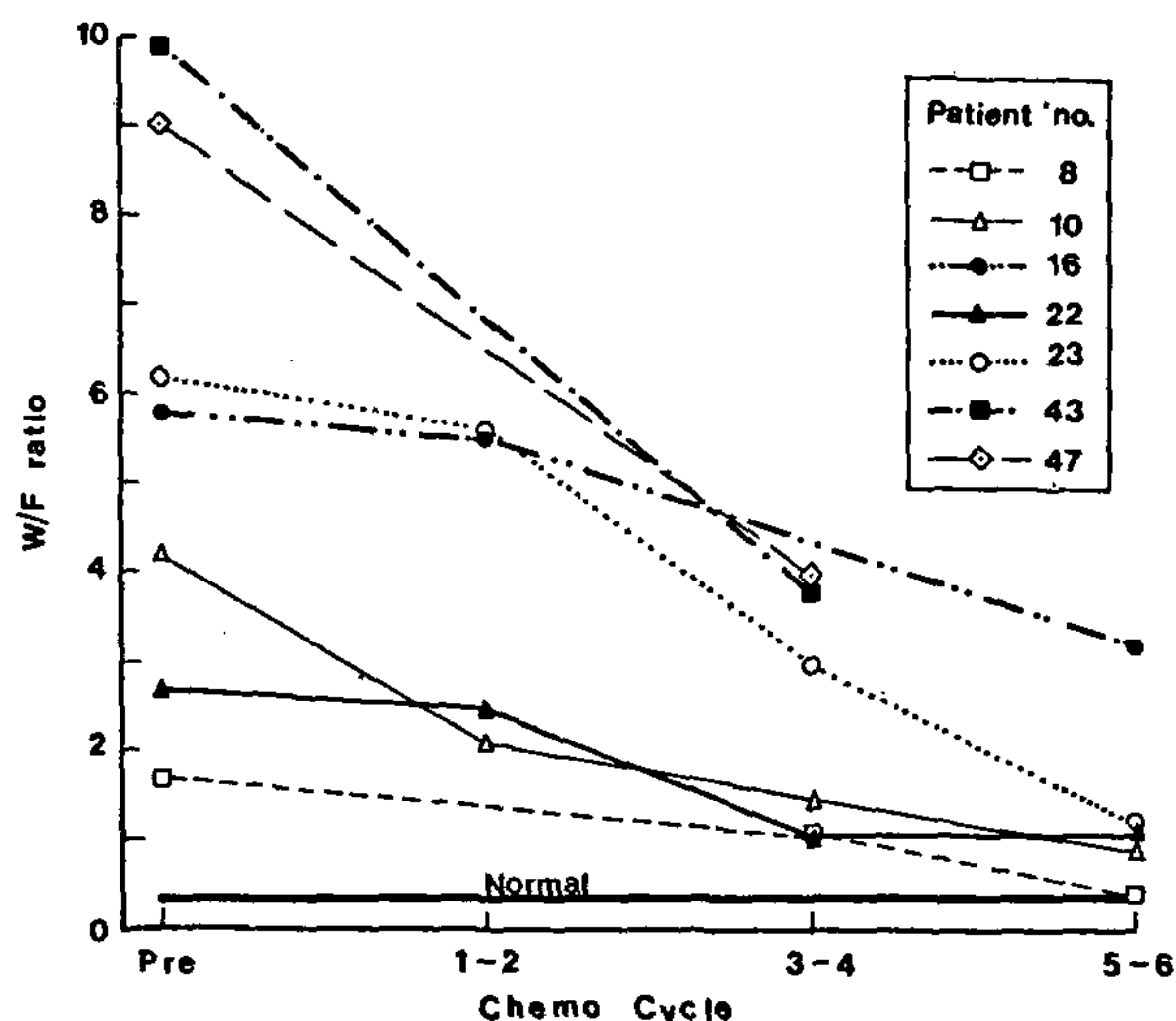


Figure 3. Plot of W/F ratio as a function of the chemotherapy cycle for seven patients studied at different time periods.

*in vitro* and *in vivo*  $^{31}\text{P}$  NMR studies have revealed high concentration of phosphomonoesters (PC and PE) in human breast tumours<sup>24-26</sup>. Similar observations have also been documented in human colon<sup>39</sup> and cerebral tumours<sup>40</sup>. It is therefore reasonable to expect choline resonance in *in vivo* proton NMR spectroscopy in breast tumours.

## Conclusions

In this review, we have clearly demonstrated the feasibility of carrying out volume localized *in vivo* proton MRS in breast cancer patients. With careful voxel localization procedures there should be little contamination from tumour-free tissue and the spectra obtained reflect the true nature of the tissue state. From the data obtained in our laboratory, it is documented that elevated W/F ratios are observed in malignant breast tissues compared to normal breast tissue from volunteers and from the contralateral unaffected breast of the patients. Moreover, in the case of patients receiving neoadjuvant chemotherapy resulting in reduction in the primary tumour size, the W/F ratio shows a decrease which is statistically significant. The observed trend of reduction in W/F ratios provides a noninvasive indicator of favourable clinical outcome of neoadjuvant chemotherapy for locally advanced breast cancers. The continued development of *in vivo* MRS and the correlation of MRS data with histopathological analysis will not only enable us to understand the biochemical mechanisms but will also serve to promote the implementation of *in vivo* MRS as a clinical tool for monitoring and assessing the

response of breast cancers to neoadjuvant chemotherapy.

1. NCRP (National Cancer Registry Programme), Biennial Report 1988-1989, An Epidemiological Study, Indian Council of Medical Research, New Delhi, 1992.
2. WHO Bull., 1990, 68, 245.
3. Feig, S. A., *Radiology*, 1988, 167, 659-665.
4. Donegan, W. L., *N. Engl. J. Med.*, 1992, 327, 937-942.
5. Winchester, D. P., Bemstin, J. R., Paige, M. L. and Christ, M. L., *Am. Cancer Soc. Bull.*, 1988.
6. Dodd, G. D., *Cancer*, 1977, 39, 2796-2805.
7. Mahony, L. and Csima, A., *Can. J. Surg.*, 1983, 26, 262-265.
8. Walker, Q. J., Gebiski, V. and Langlands, A. O., *Med. J. Aust.*, 1989, 151, 509-512.
9. Weinreb, J. C. and Newstead, G., *Radiology*, 1995, 196, 593-610.
10. Ross, R. J., Thompson, K., Kim, R. A. and Bailey, R. A., *Radiology*, 1982, 143, 195-205.
11. Heywang, S. H., Hahn, D., Schmidt, H., Krischke, I., Eiermann, W., Bassermann, R. and Lissner, J., *J. Comput. Assit. Tomogr.*, 1986, 10, 199-204.
12. Revel, D., Brasch, R. C., Paajanen, H., Rosenau, W., Grodd, B., Engelstad, B., Fox, P. and Winkelhake, J., *Radiology*, 1986, 15, 319-323.
13. Kaiser, W. A. and Zeitler, E., *Radiology*, 1989, 170, 681-686.
14. Stack, J. P., Redmond, O. M., Codd, M. B., Dervan, P. A. and Ennis, J. T., *Radiology*, 1990, 174, 491-494.
15. Pierce, W. B., Harms, S. E., Flamig, D. P., Griffly, R. H., Evans, W. P. and Hagans, J. E., *Radiology*, 1991, 181, 757-763.
16. Harms, S. E., Flamig, D. P., Hesley, K. L., Meiches, M. D., Jensen, R. A., Evans, W. P., Savino, D. A. and Wells, R. V., *Radiology*, 1993, 187, 493-501.
17. Hoffman, U., Brix, G., Knoop, M. V., Heb, T. and Lorenz, W. J., *Magn. Reson. Med.*, 1995, 33, 506-514.
18. Abraham, D. C., Jones, R. C., Jones, S. E., Cheek, J. H., Peters, G. N., Knox, K. N., Grant, M. D., Hampe, D. W., Savino, D. A. and Harms, S. E., *Cancer*, 1996, 78, 91-100.
19. Mountford, C. E., Lean, C., Mackinnon, W. A. and Russel, P., in *Annual Reports on NMR Spectroscopy* (ed. Webb, G. A.), Academic Press, London, 1993, vol. 27, pp. 173-215.
20. Delikanty, E. J., Russel, P., Hunter, J. C., Hancock, R., Atkinson, K. H., Caroline van Haaften-Day and Mountford, C. E., *Radiology*, 1993, 188, 791-796.
21. Negendank, W., *NMR Biomed.*, 1992, 5, 303-324.
22. Gribbestad, I. S., Fjosne, H. E., Hangen, O. A., Nilsen, G., Krane, J., Petersen, S. B. and Kvinnsland, S., *Anti Cancer Res.*, 1993, 13, 1973-1980.
23. Gribbestad, I. S., Nilsen, G., Fjosne, H. E., Kvinnsland, S. and Krane, J., *NMR Biomed.*, 1994, 7, 182-196.
24. Degani, H., Horowitz, A. and Itzhak, Y., *Radiology*, 1986, 161, 53-56.
25. Degani, H., in *NMR in Physiology and Biomedicine*, Academic Press, New York, 1994, pp. 329-351.
26. Sijens, P. E., Wijrdeman, H. K., Moreland, M. A., Bakker, C. J. G., Vermenten, J. W. A. and Luyten, P. R., *Radiology*, 1988, 169, 615-620.
27. Twelves, C. J., Porter, D. A., Lowry, M., Dobbs, N. A., Graves, P. A., Smith, M. A., Rubens, R. D. and Richards, M. A., *Br. J. Cancer*, 1994, 69, 1151-1156.
28. Twelves, C. J., Lowry, M., Porter, D. A., Dobbs, N. A., Graves, P. E., Smith, M. A. and Richards, M. A., *Br. J. Radiol.*, 1994, 69, 36-45.
29. Doyle, V. L., Howe, F. A., Stubbs, M., Gogas, H., Mansi, J. and Griffiths, J. R., 5th Annual Meeting of the Int. Soc. Magn. Reson. Med. (Abstr.), 1997, p. 1153.

30. Jagannathan, N. R., Singh, M., Govindaraju, V., Raghunathan, P., Coshic, O., Julka, P. K. and Rath, G. K., *NMR Biomed.*, 1998, **11**, 414-422.
31. Frahm, J., Merboldt, K. D. and Hanicke, W., *J. Magn. Reson.*, 1987, **72**, 502-508.
32. Gilligan, P., Flangan, F. L., Redmond, O. M., Walsh, D., Carney, D. N. and Ennis, J. T., 5th Annual Meeting of the Int. Soc. Magn. Reson. Med. (Abstr.), 1997, p. 1378.
33. Roebuck, J. R., Lenkinski, R. E. and Schnall, M. D., 4th Annual Meeting of the Int. Soc. Magn. Reson. Med. (Abstr.), 1996, p. 1247.
34. Bakker, C. J. G. and Vriend, J., *Phys. Med. Biol.*, 1983, **33**, 331-340.
35. Mackinnon, W. B., Huschtscha, L., Dent, K., Hancock, R., Paraskeva, C. and Mountford, C. E., *Int. J. Cancer*, 1994, **59**, 248-261.
36. Doyle, V. L., Howe, F. A., Stubbs, M., Gogas, H., Mansi, J. and Griffiths, J. R., 5th Annual Meeting of the Int. Soc. Magn. Reson. Med. (Abstr.), 1997, p. 1153.
37. Jagannathan, N. R., Mahesh Kumar, Raghunathan, P., Coshic, O., Julka, P. K. and Rath, G. K., *The Breast* (submitted for publication)
38. Jagannathan, N. R. and Sendhilvelan, S., *Appl. Magn. Reson.*, 1993, **5**, 357-367.
39. Kasiomos, J. N., Merchant, T. E., Gierke, L. W. and Glonck, T., *Cancer Res.*, 1990, **50**, 527-532.
40. Den Hollander, J. A., Luyten, P. R., Marien, A. J. H., Segebarth, C. M., Baleriaux, D. F., De Beer, R. and Va Ormond, D., *Magn. Reson. Quat.*, 1989, **5**, 152-168.

ACKNOWLEDGEMENTS. N.R.J. thanks Profs. Indira Nath and G. Govil for their continued interest, support, and encouragement. Financial support from the Department of Science and Technology, (DST) Government of India (SP/SO/B-27/95), is gratefully acknowledged.