

LETTER TO THE EDITOR

Response to high-dose dexamethasone for acquired pure red cell aplasia following ABO-mismatched allogeneic stem cell transplantation

Bone Marrow Transplantation (2006) 37, 1149–1150.
doi:10.1038/sj.bmt.1705378; published online 8 May 2006

We report a case of pure red cell aplasia (PRCA) following allogeneic peripheral blood stem cell transplantation (PBSCT) for aplastic anemia with major ABO mismatch that proved resistant to all standard treatment options including oral prednisolone, reduction in immunosuppressive treatment, erythropoietin (EPO) and Rituximab. Finally, high-dose dexamethasone for 4 days resolved the PRCA in our patient, 388 days after SCT and 40 days after the first dose of dexamethasone.

A 38-year-old male with severe aplastic anemia underwent allogeneic PBSCT in October 2003 from an HLA-matched sibling donor. The preparative regimen consisted of fludarabine 180 mg/m² over 6 days, ATGAM (Pharmacia & Upjohn Company, Kalamazoo, Michigan, USA) 40 mg/kg over 4 days and busulphan 8 mg/kg over 2 days. Peripheral blood stem cell transplantation was performed on 17 November 2003 and 18 November 2003. The recipient was B Rh positive while the donor was A Rh positive; other minor blood groups antigens were not tested. The recipient's pre-transplant anti-A IgM (saline) titer was 1:64 and IgG (Coombs) titer was 1:128. A total of 200 ml of PBSC was infused with a cell dose of 3.79×10^8 mononuclear cells/kg. No manipulation of the graft was carried out and there were no hemolytic complications. Cyclosporine and short course methotrexate were used as GVHD prophylaxis. An absolute neutrophil count of $> 500/\text{mm}^3$ was achieved on day +14, whereas an unsupported platelet count of $> 20\,000/\text{mm}^3$ was achieved on day +13.

Following the transplant the patient continued to run a low hemoglobin (6.2–7.8 gm/dl) with a low reticulocyte count (0.1–0.3%) despite complete donor chimerism on VNTR analysis, and even after day +60 he continued to require blood transfusions every 2 weeks.

Bone marrow examination confirmed the diagnosis of PRCA with less than 5% erythroid precursors and the following therapies were tried without significant reduction in transfusion requirement or increase in reticulocyte count:

1. Oral prednisolone – 40 mg daily for 6 weeks from day +127 to +174.
2. Rituximab –375 mg/m² on day +183. This led to a fourfold reduction in IgM and IgG titer but with no reticulocyte response.
3. Erythropoietin – 10000 IU thrice weekly from day +285 to day +315, 16 doses for 4 weeks, which

resulted in a decrease in anti-A titers at the end of therapy to 1:2 IgM and 1:4 IgG.

4. Cyclosporine was reduced with the aim of facilitating graft-versus-recipient depletion of residual B lymphocytes. Dose reduction was started on day +240 and the drug was stopped on day +326.
5. Finally, he was treated with high-dose dexamethasone 40 mg intravenously for 4 days from day +348 to day +352. He had a significant response to this therapy, with an increase in hemoglobin from 7.3 gm/dl to 8.5 gm/dl (day +353) and an increase in reticulocyte count from 0.2 to 1.2%. By day +374, the hemoglobin levels had increased to 11.3 gm/dl with a reticulocyte count of 2.4%. His blood group had converted to A Rh positive and the anti-A titers further reduced to 1:2 IgM and 1:2 IgG by day +388 (Figure 1). The hemoglobin steadily increased to 11.9 gm% with a reticulocyte count of 1.8% on day +416 and remained stable until discharge on day +420. He continues to be asymptomatic with a normal hemoglobin level and reticulocyte count, 27 months after PBSCT. Chimerism analysis, using the th01 marker on peripheral blood, showed complete donor chimerism.

Pure red cell aplasia occurs in around 20% of patients receiving transplants with major ABO incompatibility and the post transplant increase of isoagglutinins is a significant predictor of PRCA. Presence and persistence of isoagglutinins may delay red cell engraftment and be the cause of PRCA.¹ The mechanism of prolonged PRCA after ABO-incompatible BMT is complement-mediated immune

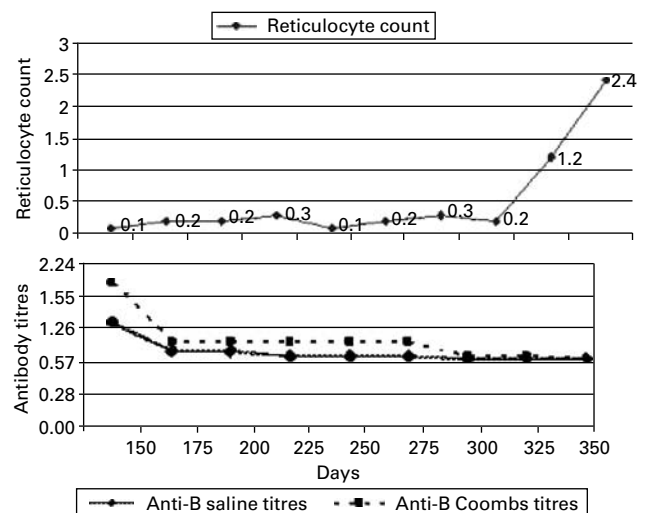


Figure 1 Response of reticulocyte count and antibody titres over time.

destruction of erythroid progenitors past the stage of BFU-E differentiation.² The persistence of isoagglutinins is due to antibody-producing plasma cells of recipient origin which are not destroyed by the conditioning regimen.³ A graft-vs-plasma cell effect is thought to be responsible for the rapidity of isoagglutinin disappearance after transplantation.³ Immunological changes due to withdrawal of cyclosporin A,⁴ or development of GVHD, are followed by rapid resolution of delayed rbc engraftment. Many treatment options have been reported in the literature including high-dose EPO,⁵ plasma exchange, immunoadsorption, antithymocyte globulin, Rituximab,⁶ DLI, low-dose steroids⁷ and bolus methylprednisolone. Evaluation of the efficacy of any treatment is difficult because of the eventual spontaneous resolution of PRCA post-transplantation.⁸ In this patient, low-dose oral prednisolone, single-dose Rituximab, erythropoietin and induction of chronic GVHD by reduction of cyclosporine were all ineffective.

High-dose dexamethasone⁹ is effective in refractory chronic ITP and this was therefore tried, with good response in this patient.

Therapy with dexamethasone is a low cost therapeutic option for the management of post-transplant PRCA in an ABO-mismatched transplant.

UR Deotare, A Vishwabandya, V Mathews, B George,
A Srivastava and M Chandy
Department of Hematology, Christian Medical College,
Vellore, Tamil Nadu, India
E-mail: mannen@cmevelloc.ac.in

References

- Lee J-H, Lee J-H, Choi S-J, Kim S, Seol M, Kwon SW *et al.* Changes of isoagglutinin titres after ABO-incompatible allogeneic stem cell transplantation. *Br J Hematol* 2003; **120**: 702–710.
- Sahovic EA, Flick J, Graham CD, Stuart RK. Case report: isoimmune inhibition of erythropoiesis following ABO-incompatible bone marrow transplantation. *Am J Med Sci* 1991; **302**: 369–373.
- Mielcarek M, Leisenring W, Torok-Storb B, Storb R. Graft-versus-host disease and donor-directed hemagglutinin titers after ABO-mismatched related and unrelated marrow allografts: evidence for a graft-versus-plasma cell effect. *Blood* 2000; **96**: 1150–1156.
- Yamaguchi M, Sakai K, Murata R, Ueda M. Treatment of pure red cell aplasia after major ABO-incompatible peripheral blood stem cell transplantation by induction of chronic graft-versus-host disease. *Bone Marrow Transplant* 2002; **30**: 539–541.
- Santamaria A, Sureda A, Martino R, Domingo-Albos A, Muniz-Diaz E, Brunet S. Successful treatment of pure red cell aplasia after major ABO-incompatible T cell-depleted bone marrow transplantation with erythropoietin. *Bone Marrow Transplant* 1997; **20**: 1105–1107.
- Maschan AA, Skorobogatova EV, Balashov DN, Pashanov ED, Trakhtman PE, Schipitzina IP *et al.* Successful treatment of pure red cell aplasia with a single dose of rituximab in a child after major ABO incompatible peripheral blood allogeneic stem cell transplantation for acquired aplastic anemia. *Bone Marrow Transplant* 2002; **30**: 405–407.
- Yang MH, Hsu HC. Pure red cell aplasia after ABO-incompatible allogeneic stem cell transplantation in severe aplastic anemia with response to steroids: a case report and literature review. *Ann Hematol* 2001; **80**: 299–301.
- Gmur JP, Burger J, Schaffner A, Neftel K, Oelz O, Frey D *et al.* Pure red cell aplasia of long duration complicating major ABO-incompatible bone marrow transplantation. *Blood* 1990; **75**: 290–295.
- Anderson JC. Response of resistant idiopathic thrombocytopenic purpura to pulsed high-dose dexamethasone therapy. *N Engl J Med* 1994; **330**: 1560–1564.