

CHEST[®]

Official publication of the American College of Chest Physicians



Primary Mediastinal Choriocarcinoma

S. Prusty, J. N. Bhayana, N. C. Nayak, S. Singh, V. S. Singh, S. R. Sharma and P. P. Goel

Dis Chest 1969;56;543-546
DOI 10.1378/chest.56.6.543

The online version of this article, along with updated information and services can be found online on the World Wide Web at:
<http://chestjournal.chestpubs.org/content/56/6/543>

Dis Chest is the official journal of the American College of Chest Physicians. It has been published monthly since 1935. Copyright 1969 by the American College of Chest Physicians, 3300 Dundee Road, Northbrook, IL 60062. All rights reserved. No part of this article or PDF may be reproduced or distributed without the prior written permission of the copyright holder.
(<http://chestjournal.chestpubs.org/site/misc/reprints.xhtml>) ISSN:0096-0217



Primary Mediastinal Choriocarcinoma*

S. Prusty, M.S.,** J. N. Bhayana, M.D.,† N. C. Nayak, M.D.,‡ S. Singh, M.S.,§ V. S. Singhal, M.S.,§ S. R. Sharma, M.D.,|| and P. P. Goel, M.D.¶

Primary mediastinal choriocarcinoma is a rare entity and is peculiar only to man. Although rigid criteria such as serial biopsies of the gonads are essential to rule out the possibility of such mediastinal tumor as a metastatic lesion, a review of the literature shows that anterior mediastinum is rarely involved by the metastasis from gonadal tumors. The clinical diagnosis of such a tumor can be made by the presence of the triad of chest pain, cough and gynecomastia in a man in the third decade. The prognosis of such a lesion is uniformly hopeless irrespective of the mode of treatment. A case of primary mediastinal choriocarcinoma in a 22-year-old man has been described. This case brings the total number of cases to 16.

Choriocarcinoma, which primarily occurs in the mediastinum, besides its extreme rarity,¹ is of great interest from the point of view of histogenesis of the tumor.² Very rigid criteria have been used to diagnose this as a primary mediastinal lesion and to exclude metastatic lesions of this nature from the gonads.^{3,4} In a woman, such an exclusion obviously becomes more difficult, because of the possible elimination of the primary lesion from the uterus by abortion or by surgery from the sites of ectopic gestation.² On the other hand, it has been suggested that certain clinical features may strongly indicate the possibility of such a tumor arising primarily in the mediastinum in the male and a preoperative diagnosis can often be made with fair degree of accuracy.¹ We have recently come across a tumor of this nature in a young man which we consider to have arisen primarily in the mediastinum. The present communication is a report of this case with a review of the literature on this subject.

CASE REPORT

A 22-year-old married Hindu man was admitted to G. B. Pant Hospital on July 22, 1967, with the complaints of pain in the right side of the chest since November 1966 and low backache, cough and fever since July 1967.

*From the Department of Cardiothoracic Surgery, M. A. M. College and associated Irwin and G. B. Pant Hospitals, New Delhi, India.

**Lecturer in Cardiac Surgery; presently Assistant Professor of Cardiothoracic Surgery, All India Institute of Medical Sciences.

†Junior Consultant in Cardiac Surgery.

‡Associate Professor of Pathology, All India Institute of Medical Sciences.

§Registrar in Cardiac Surgery.

||Associate Professor of Radiology.

¶Senior Consultant in Cardiac Surgery; at present Chief Surgeon and Superintendent, Safdarjang Hospital.

In November 1966, he was treated in a hospital for acute pain in the right chest and was put on antituberculosis drugs, namely, injection of streptomycin 1 gm I. M., O. D. and isoniazid, 300 mg O. D. Since he continued to have symptoms, he was admitted in another hospital on June 16, 1967, where a diagnosis of right paracardial effusion was made, and he was discharged after four days of hospitalization, with advice to continue the same antituberculosis drugs. About four weeks later, on July 22, 1967, he was admitted to G. B. Pant Hospital with the same complaints as mentioned above and, in addition, weakness.

He was addicted to smoking and to the use of alcohol since childhood. He had been married at the age of 18 years and had two children. There was no history of any familial illness.

On examination, the patient was of average build, weighed 51 kg and looked pale. He had no cyanosis, clubbing of fingers, lymphadenopathy or edema on any part of the body. His pulse was 94 per minute, regular and the blood pressure was 130/90 mm Hg. Both the testes were small in size, measuring approximately $2 \times 1.2 \times 1$ cm. There was bilateral gynecomastia of moderate degree. Examination of the respiratory system revealed centrally situated trachea and prominence of the right anterior chest wall with a dull percussion note over it. Breath sounds were absent over the dull area but vesicular over the rest of the lung fields. The heart was clinically normal. The abdomen was soft and no tumor mass was felt. The liver was enlarged about 3 cm, below the costal margin and not tender. The spleen was not palpable. There were no ascites. The spine and the rest of the skeletal system had no abnormality.

HOSPITAL COURSE

The day after admission, the patient developed fever. His temperature ranged from 100° to 102°F, but was not accompanied by chill or rigor. It was irregular and intermittent in character. At the same time, his low backache became progressively worse, but no abnormality could be detected on clinical examination.

Blood count

The total white blood cell count was 9,200/mm,³ the differential count—polymorphonuclears 78 percent, lymphocytes 20 percent and eosinophils 2 percent. Erythrocyte sedimentation rate was 95 mm in the first hour. Hemoglobin was 8 gm per 100 ml and the results of urinalysis revealed no abnormality. X-ray film of the chest (Fig 1 and 2) showed an opacity over the right hilum suggestive of anterior mediastinal encysted pleural effusion. X-ray films of the pelvis and both hip joints did not show any detectable bony lesion.

The antituberculosis drugs were continued as before and in addition chloramphenicol (Chloromycetin) 250 mg every six hours and injections of crystalline penicillin, 100,000 units every six hours were administered.

An aspiration of the right pleural cavity was done on July 29, 1967, and 300 ml of clear, straw-colored fluid was removed. It was sterile after 48 hours of culture. On August 8, 1967, a needle aspiration done anteriorly over the radiologic zone of opacity yielded only frank blood. A chest x-ray picture taken two days later revealed increased opacity in the whole of right side. The right pleural cavity was again aspirated and 550 ml of turbid fluid was withdrawn. The fluid had a specific gravity of 1.016 and its protein content was 3.2 gm per 100 ml. Microscopic examination of the aspirated fluid revealed many

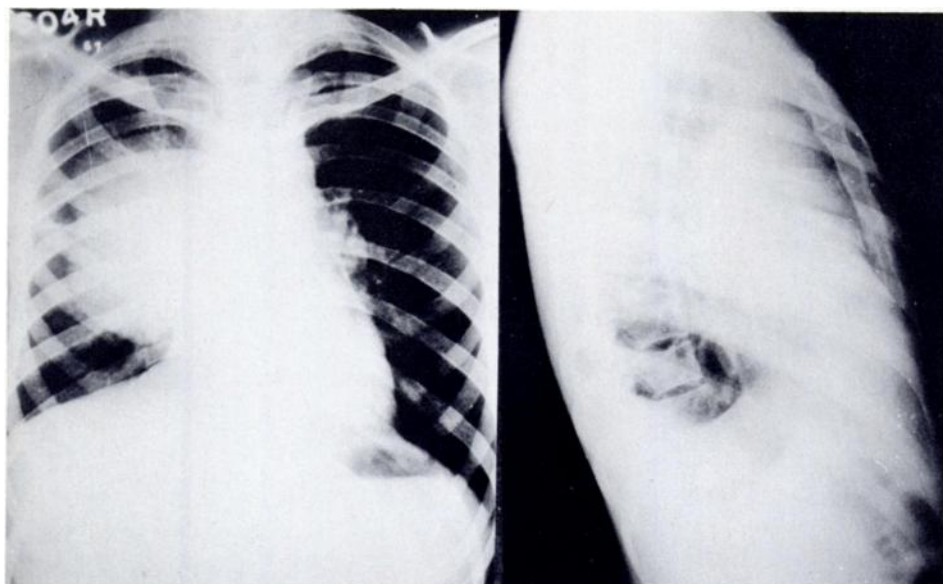


FIGURE 1 (Left). PA view of the chest shows homogenous opacity over the right paracardiac region with a distinct lateral outline. FIGURE 2 (Right). Right lateral view of the chest showing the opacity in the region of the anterior mediastinum.

red blood cells and occasional mesothelial cells but no malignant cells were seen.

Four weeks after his admission, the patient developed swelling of the neck and face which progressively increased simulating a superior vena caval syndrome. The dull area over the right chest wall increased and simultaneously a soft, fluctuant, rounded mass measuring 5×2.5 cm was noted over the left eighth rib along the midclavicular line. Abdominal examination revealed a diffuse, nontender, intra-abdominal mass over the right iliac fossa fixed to the iliac bone. The testes were conspicuously smaller than at the time of his admission. The result of rectal examination gave an impression of a fullness over the right side. X-ray film of the pelvis revealed erosion of the right iliac bone. The patient's blood picture at this time was hemoglobin 8.0 gm per 100 ml, hematocrit, 28 percent, total WBC $10,500/\text{mm}^3$ —polymorphonuclears and lymphocytes 12 percent. The erythrocyte sedimentation rate was 100 mm in the first hour. Serum protein was 6.7 gm per 100 ml with albumin 3.4 gm per 100 ml and globulin 3.3 gm per 100 ml.

A tentative clinical diagnosis of mediastinal choriocarcinoma with metastases in the rib and iliac bones was made at that stage.

An excisional biopsy of the left eighth rib was done under local anesthesia on August 22. The mass appeared

to be highly vascular, soft and completely eroding the rib (Fig 3).

Pathology Report

The surgical specimen was comprised of a 5 cm length of rib with a rounded tumor 3 cm in diameter, occupying its central portion and bulging through the thinned out cortex. The tumor had a somewhat lobulated surface and appeared well circumscribed, surrounded by a thin capsule (Fig 3). Its cut surface presented a soft, markedly necrotic and hemorrhagic appearance with pathologic fracture and destruction of the rib (Fig 4). The tumor was friable. The inner surface of the rib revealed a smooth fibro-osseous tissue stretched out over the tumor.

Histology

The tumor was markedly necrotic with large areas of hemorrhage. In the viable portion, it was comprised of sheets and groups of pleomorphic cells principally of two different types (Fig 5). The majority appeared large and polygonal in shape with large rounded vesicular nuclei and a fair amount of pale staining cytoplasm. A smaller number of cells were more irregular in outline with denser eosinophilic cytoplasm and dark oval nuclei. Multinucleated cells and mitotic figures were seen in many areas. The tumor cells were seen infiltrating the surrounding soft tissues and fragments of dead bone were present inside the tumor (Fig 6). New bone formation and fibrosis were apparent in some areas at the periphery of the lesion. The histological features were those of a metastatic choriocarcinoma.

Since the day of biopsy, the patient's general condition progressively deteriorated. He was soon unable to stand. The swelling over the face and neck progressively increased in contrast to the marked atrophy of the lower extremities. The testes were reduced to infantile size. His hemoglobin fell to 5.0 gm per 100 ml.

Having confirmed the diagnosis of choriocarcinoma, the patient was put on methotrexate, 5 mg twice daily but this drug had to be stopped in a week's time as the total WBC count fell to $3,600/\text{mm}^3$. The patient became progressively dyspneic and died on September 16, 1967.

Tests for chorionic gonadotropin hormones could not be carried out. Permission for autopsy was not granted.

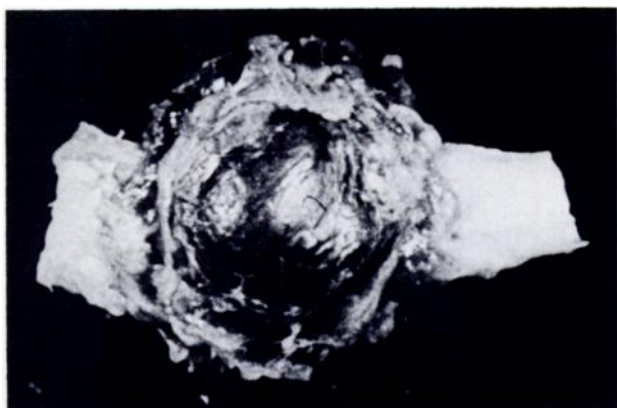


FIGURE 3. Resected rib with the tumor which appears rounded, well-circumscribed and highly vascular.

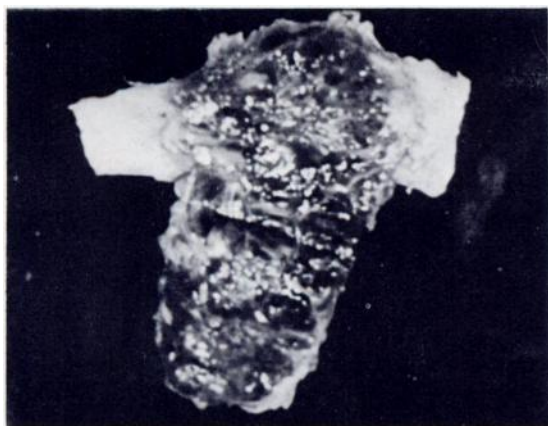


FIGURE 4. Cut surface of the tumor reveals soft and necrotic lesion with extensive hemorrhage.

DISCUSSION

Marchand⁵ in 1895, was the first to suggest that chorioepitheliomas in a woman originate in the chorionic villi. As early as 1902, Schlagenhafer⁶ described the development of chorioepithelioma in

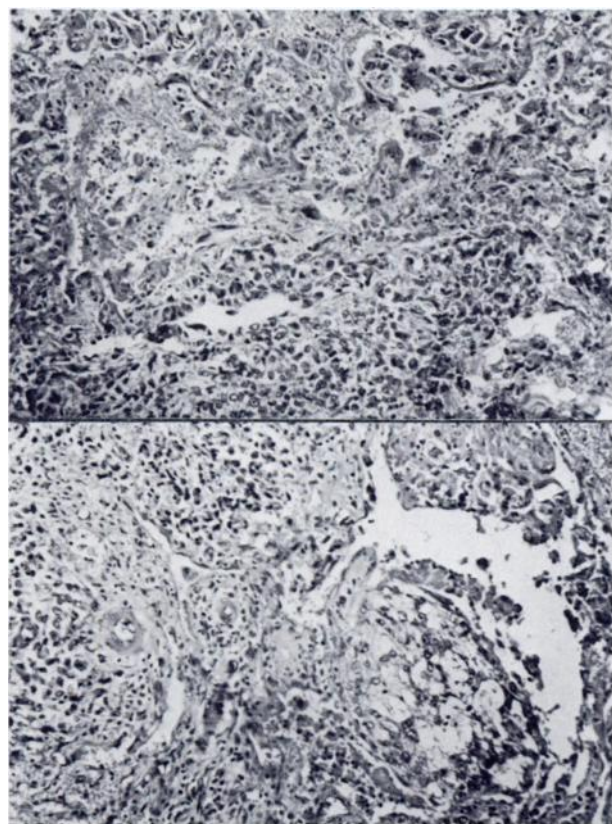


FIGURE 5 (upper). General histologic appearance of the tumor in a viable zone. Areas of hemorrhagic necrosis are intermingled with syncytio (central portion) and cyto (lower portion) trophoblastic elements. Hematoxylin and eosin, $\times 120$. FIGURE 6 (lower). Another representative area of the lesional tissue showing cyto (left half) and syncytio (right half) trophoblasts in close association. Hemoxilyn and eosin, $\times 120$.

the germ cells of the testis or of teratomatous tissue. Since then, many theories have been advanced to explain the growth of these tumors in extragenital sites such as in the mediastinum, peritoneal organs and retroperitoneum.⁷⁻¹⁰ It is apparent from several such studies that abnormal inclusions of germ cells can occur anywhere along the urogenital ridge extending from C-6 to L-3.

The rarity of a primary choriocarcinoma in the mediastinum has prompted many discussions regarding the essentials for its unequivocal diagnosis. Prym³ in 1927 stressed that in a case of extragenital choriocarcinoma even a scar in the testicle may represent the involution of the primary tumor. Since then, very rigid criteria have been adopted, to establish an extragenital choriocarcinoma as a true primary tumor. It has been generally accepted that the gonads be carefully examined clinically and histologically by study of serial sections before excluding a primary tumor in them. Nevertheless, Frank¹¹ in 1932 clearly established that the mediastinum may very well be the primary site for an extragenital teratoma. This has been supported by Ewing¹² in 1940, who stated that the sex cells may occur anywhere along the entire length of the embryonal entoderm and may reasonably be found in the mediastinum. Lynch and Blewett¹³ suggested that testicular scars when seen in patients with extragenital tumors may very well be posttraumatic or regressing foci of metastasis rather than the site of primary tumor. They also cited Grieling's series of 220 metastasizing testicular tumors in which no case had evidence of anterior mediastinal metastasis, which goes to prove that the possibility of a tumor to occur in the anterior mediastinum as a result of secondary metastasis from the testis must be extremely remote. In fact, tumors of germ cell origin such as teratoma, teratocarcinoma, choriocarcinoma and seminoma are believed to be common primary tumors of the anterior mediastinum.¹⁴

The clinical, radiological and pathological features in our patient lead us to the conclusion that the tumor had primarily arisen in the mediastinum and had metastasized to the left eighth rib and right iliac bone. The histology of the tumor was characteristic of choriocarcinoma with abundant growth of both syncytio and cytotrophoblasts accompanied by extensive necrosis and hemorrhage. It was extremely unlikely, though not impossible that the mediastinal tumor was a metastasis from a primary in the testes. The progressive atrophy of the testes, finally ending in their infantile size, was a distinct indication of a hormonal effect and not of a neoplastic lesion which was widely metastasizing. The

lesions in the rib and iliac bone which appeared during his last hospitalization, were metastases from the original tumor in the mediastinum.

A total of 15 cases of primary mediastinal choriocarcinoma have so far been documented in the literature.¹⁵ It is believed that abnormal inclusions along the urogenital ridge may remain dormant until puberty or later sex life when some stimulus might cause them to mature and develop to a tumor mass.^{1,16} As such, the majority of patients having extragenital choriocarcinoma, as reported in the literature belong to the second, third and fourth decades of life.² Our patient falls in this age group. Although primary extragenital choriocarcinoma is known to occur in both sexes, the mediastinal primary is peculiar only to men.^{15,16}

Usually patients with extragenital choriocarcinoma present themselves within one to three months of the onset of disease. Only in a few cases has the duration been longer, varying from 15 months to 4 years.¹⁷⁻²⁰ The presence of a mediastinal tumor alone, may give minimal symptoms, whereas its metastasis, particularly that to the lung, frequently bring the patient with the complaints of cough, hemoptysis and chest pain. Hematuria and cerebral disorders might be other presenting features of metastasis. The presence of the triad of chest pain, cough, and gynecomastia in the male between 20 to 30 years of age with a radiologically demonstrable anterior mediastinal mass should strongly suggest the diagnosis of choriocarcinoma.¹ The lung is most frequently involved by metastasis, followed closely by the liver. Distant spread might also occur in the lymph nodes, kidney, spleen, pancreas, thyroid, bone, intestine, posterior pituitary and nasopharynx.^{12,15,16} Varying degrees of testicular atrophy is the peculiarity in the majority of the cases having primary mediastinal choriocarcinoma.¹⁶ Similarly, the other picture of hormonal imbalance due to excessive production of chorionic gonadotropin is the appearance of gynecomastia in over 50 percent of cases.^{2,15,16}

The chest roentgenogram in these cases gives an uniformly dense opacity in the anterior mediastinum with or without any significant displacement of the mediastinal structures. Rapid increase in the density of growth along with downhill course of the patient gives an important clue to the clinical diagnosis.

Once the diagnosis is made the subsequent course of the disease becomes very rapid, usually ending fatally in a matter of days or weeks.^{1,2,15}

No successful line of treatment is as yet available for this disease.^{1,15,16} Surgical excision and radiotherapy, both give poor results. It has been shown

that chemotherapeutic agents like methotrexate and 6-mercaptopurine reduce the gonadotropin titer but this effect is not long lasting.

ACKNOWLEDGMENT: We are grateful to the Superintendent, G. B. Pant Hospital for allowing us to report this case. We are thankful for the help of the Department of Pathology, All India Institute of Medical Sciences. We are indeed thankful to Mr. Nagraj for his excellent secretarial help.

REFERENCES

- 1 YURICK, B.S., AND OFFOMAN, R.E.: Primary mediastinal choriocarcinoma, *Radiology*, 75:901, 1960.
- 2 FINE, G., SMITH, R.W., JR., AND PACTER, M.R.: Primary extragenital choriocarcinoma in the male subject; case report and review of the literature, *Amer. J. Med.*, 32: 776, 1962.
- 3 PRYM, P.: Spontanteilung eines bosartigen, wahrscheinlich chorionepitheliomatosen Gewaches in Hoden, *Virchow Arch. Path. Anat.*, 265:239, 1927.
- 4 HIRSCH, O., ROBBINS, S.L., AND HONGTTON, J.D.: Mediastinal chorionepithelioma in a male, a case report, *Amer. J. Path.*, 22:833, 1946.
- 5 MARCHAND, F.: Über die so generation 'Decidualin Geschwiilste in Anshnlss und normale Geburt, Abort, Blasen mole and Extraule ninschwangerschaft, *Monatsch. Geburtsh. Gynak.*, 1:419, 515, 1895.
- 6 SCHLAGENHANFER, F.: Über das vorkommen chorionepitheliom und tranbenmolenartiger Wucherungen in Teratomen, *Wien. Klin. Wschr.*, 15:571; 604, 1902.
- 7 MILLER, J., AND BROWNE, F.J.: Extragenital chorionepithelioma of congenital origin, *J. Obstet. Gynaec. Brit. Comm.*, 29:48, 1922.
- 8 AREY, L.B.: *Developmental anatomy: a textbook and laboratory manual of embryology*, (5th ed), W. B. Saunders Co., Philadelphia, 1946, chap. 14.
- 9 PATTEN, B.M.: *Human embryology*, Blakiston Company, New York, 1946, chap. 18.
- 10 FRIEDMAN, N.B.: Comparative morphogenesis of extragenital and gonadal teratoid tumours, *Cancer*, 41:266, 1951.
- 11 FRANK, R.T.: Discussion of Kantrowitz, A.R., in Extragenital chorionepithelioma in a man, *Arch. Path.*, 13:187, 1932.
- 12 EWING, J.: *Neoplastic disease*, W. B. Saunders Co., Philadelphia, 1940, p 1047.
- 13 LYNCH, M.J.G., AND BLEWETT, G.L.: Choriocarcinoma arising in the male mediastinum, *Thorax*, 8:157, 1953.
- 14 KLEITSCH, W.P., TARICEO, A., AND HASLAM, G.J.: Primary seminoma (germinoma) of the mediastinum, *Amer. Thorac. Surg.*, 3:249, 1967.
- 15 WENGER, M.E., DINES, D.E., AHMANN, D.L., AND GOOD, C.A.: Primary mediastinal choriocarcinoma, *Mayo Clin. Proc.*, 43:570, 1968.
- 16 MAGOVERN, G.J., AND BLADES, B.: Primary extragenital chorionepithelioma in the male mediastinum, *J. Thorac. Cardiovasc. Surg.*, 35:378, 1958.
- 17 ARENDT, J.: Das chorionepitheliom des mannes, *Fortschr. Roentgenstr.*, 43:728, 1931.
- 18 KANTROWITS, A.R.: Extragenital chorionepithelioma in a male, *Aber. J. Path.*, 10:531, 1934.
- 19 LAIPPLY, T.C., AND SHIPLEY, R.A.: Extragenital choriocarcinoma in the male, *Amer. J. Path.*, 21:921, 1945.
- 20 DUPREZ, A., FLAMET, F., AND HOFNANS, A.F.: Mediastinal choriocarcinomas with cardiac involvement in male, *Acta Chir. Belg.*, 57:808, 1958.

Primary Mediastinal Choriocarcinoma

S. Prusty, J. N. Bhayana, N. C. Nayak, S. Singh, V. S. Singh, S. R. Sharma and P. P. Goel

Dis Chest 1969;56; 543-546

DOI 10.1378/chest.56.6.543

This information is current as of November 27, 2010

Updated Information & Services

Updated Information and services can be found at:

<http://chestjournal.chestpubs.org/content/56/6/543>

Permissions & Licensing

Information about reproducing this article in parts (figures, tables) or in its entirety can be found online at:

<http://www.chestpubs.org/site/misc/reprints.xhtml>

Reprints

Information about ordering reprints can be found online:

<http://www.chestpubs.org/site/misc/reprints.xhtml>

Citation Alerts

Receive free e-mail alerts when new articles cite this article. To sign up, select the "Services" link to the right of the online article.

Images in PowerPoint format

Figures that appear in *CHEST* articles can be downloaded for teaching purposes in PowerPoint slide format. See any online figure for directions.

