

Case report

Ribavirin therapy for hepatitis E virus-induced acute on chronic liver failure: a preliminary report

Rohit Goyal¹, Ajay Kumar¹, Subrat K Panda², Shashi B Paul³, Subrat K Acharya^{1*}

¹Department of Gastroenterology and Human Nutrition, All India Institute of Medical Sciences, New Delhi, India

²Department of Pathology, All India Institute of Medical Sciences, New Delhi, India

³Department of Radiodiagnosis, All India Institute of Medical Sciences, New Delhi, India

*Corresponding author e-mail: subratacharya@hotmail.com

Hepatitis E virus (HEV) is a common cause of acute on chronic liver failure (ACLF) in HEV hyperendemic regions with high mortality. Treatment for HEV-induced ACLF is currently not available. Recently, efficacy of ribavirin in genotype 3 chronic hepatitis E patients has been reported; however, whether ribavirin is effective in genotype 1 HEV infection is not yet known. The present study includes four patients with HEV-induced ACLF treated with ribavirin in a genotype 1 HEV hyperendemic region. Diagnosis of ACLF was made by conventional

criteria and HEV as the cause of ACLF was confirmed by detection of HEV RNA by reverse transcriptase PCR. Ribavirin dose ranged from 200 to 600 mg/day and was used for a median duration of 12 (range 3–24) weeks. All patients had undetectable HEV in 3–8 weeks, survived and none had serious adverse effects. This preliminary observation from a single centre indicates that ribavirin may be an effective therapeutic agent for HEV-induced ACLF and a randomized control trial is needed to establish its efficacy.

Introduction

Hepatitis E virus (HEV) is the most common cause of acute hepatitis in India [1] and HEV superinfection frequently causes acute on chronic liver failure (ACLF) in HEV hyperendemic regions [2–7]. In a previous study from our centre [7], 50% of ACLF patients had HEV RNA in their sera with rapid hepatic decompensation and a high mortality rate. Recent reports indicate that ribavirin could eradicate HEV in renal transplant patients with chronic HEV infection [8–10]. In another report, ribavirin was effective in eradicating HEV in patients with alcoholic liver disease and HEV superinfection [11]. All these case reports included patients with genotype 3 HEV infections [8–11]; however, in the Indian subcontinent, human HEV infections are predominantly caused by genotype 1 [12]. The efficacy of ribavirin against HEV genotype 1 is not yet reported. The present report includes four patients with HEV-induced ACLF from India, in whom HEV infection was eradicated by ribavirin, resulting in improvement of liver failure and survival. This preliminary observation provides *prima facie* evidence of efficacy of ribavirin as a therapeutic agent against HEV in HEV-induced ACLF with consequent survival benefit providing rationale to conduct randomized controlled trials.

Case 1

A 50-year-old male was diagnosed with HBV-associated cirrhosis with hepatocellular cancer (HCC) in June 2006. He presented with fatigue and had abnormal liver function tests (LFTs; serum bilirubin 1.3 mg/dl, alanine transaminase [ALT] 75 IU/l, serum albumin 3.0 g/dl and international normalized ratio [INR] 1.1). Hepatitis B surface antigen (HBsAg), hepatitis B e antigen (HBeAg), antibodies against hepatitis B core antigen (anti-HBc) and HBV DNA (10⁷ copies/ml) were detected in his sera. Triphasic CT and MRI detected multifocal HCC. He achieved HBeAg seroconversion with undetectable HBV DNA after 48 weeks of treatment with entecavir (0.5 mg/day), which was continued afterwards. Transarterial chemoembolisation (TACE) using cisplatin and doxorubicin was performed in June 2006 to treat HCC. He had recurrence of HCC in June 2009, which was retreated with TACE. He had high-grade oesophageal varices that were eradicated with endoscopic variceal ligation. The patient was followed-up at 3 monthly intervals. In January 2011, clinically overt ascites was documented following a brief febrile illness. The MRI

and fluorodeoxyglucose positron emission topography documented patent portal and hepatic veins and absence of HCC recurrence. HBV DNA was undetectable. LFTs revealed serum bilirubin of 0.9 mg/dl and ALT 44 IU/l, but serum albumin had decreased to 2.4 g/dl from 2.7 g/dl over a period of 6 months. Serum ascites albumin gradient was high and there was no evidence of spontaneous bacterial peritonitis. We suspected HEV superinfection and detected HEV RNA (10^7 copies/ml) in his sera by reverse transcriptase (RT)-PCR [13]. Ribavirin (600 mg/day in two divided doses) was started. HEV RNA became undetectable after 4 weeks of treatment and remained undetectable until his last visit in August 2011 with consequent improvement of his subjective symptoms and ascites with normal LFTs and undetectable HBV DNA.

Case 2

A 16-year-old male was diagnosed with compensated type 1 autoimmune cirrhosis in October 1996. His initial symptoms included low-grade fever and polyarthritides. He had abnormal LFTs (serum bilirubin 0.2 mg/dl, ALT 240 IU/l, serum albumin 4.2 g/dl and INR 1.2). Serological markers for hepatitis viruses (HBsAg, anti-HBc, anti-HCV, HCV RNA, IgM anti-hepatitis-A-virus [HAV] and IgM anti-HEV) were negative. Anti-nuclear antibody (ANA) and anti-smooth muscle antibody (ASMA) were positive (titres $>1:80$). Liver biopsy revealed cirrhosis with interface hepatitis. With prednisolone (1 mg/kg/day) and azathioprine (50 mg/day) treatment, he achieved clinical and biochemical remission in 4 weeks. He was maintained on low-dose immunosuppression (prednisolone 10 mg/day and azathioprine 25 mg/day) and followed-up at 3–6 months. Liver biopsy in December 2004 documented marked histological improvement. In March 2011, he had acute hepatitis (serum bilirubin 3.4 mg/dl, aspartate aminotransferase [AST] 844 IU/l, ALT 1,621 IU/l, alkaline phosphatase 327 IU/l, serum albumin 4.0 g/dl and INR 1.1). He was diagnosed to have acute HBV and HEV coinfection (HBsAg-, HBeAg-, IgM-anti-HBc-positive; HBV DNA $>10^7$ copies/ml and HEV RNA 10^6 copies/ml). He deteriorated in 2 weeks (serum bilirubin 16.7 mg/dl and INR 2.07). A diagnosis of ACLF was made. Treatment with tenofovir 300 mg/day and ribavirin 400 mg/day in two divided doses was started and liver functions subsequently improved. After 3 weeks, HEV RNA became undetectable; however, haemoglobin levels decreased from 14.5 g/dl to 9.6 g/dl and ribavirin was discontinued. Tenofovir and low-dose immunosuppression were continued. At the 6-month follow-up, he remained asymptomatic with normal LFTs and undetectable serum HEV RNA and HBV DNA.

Case 3

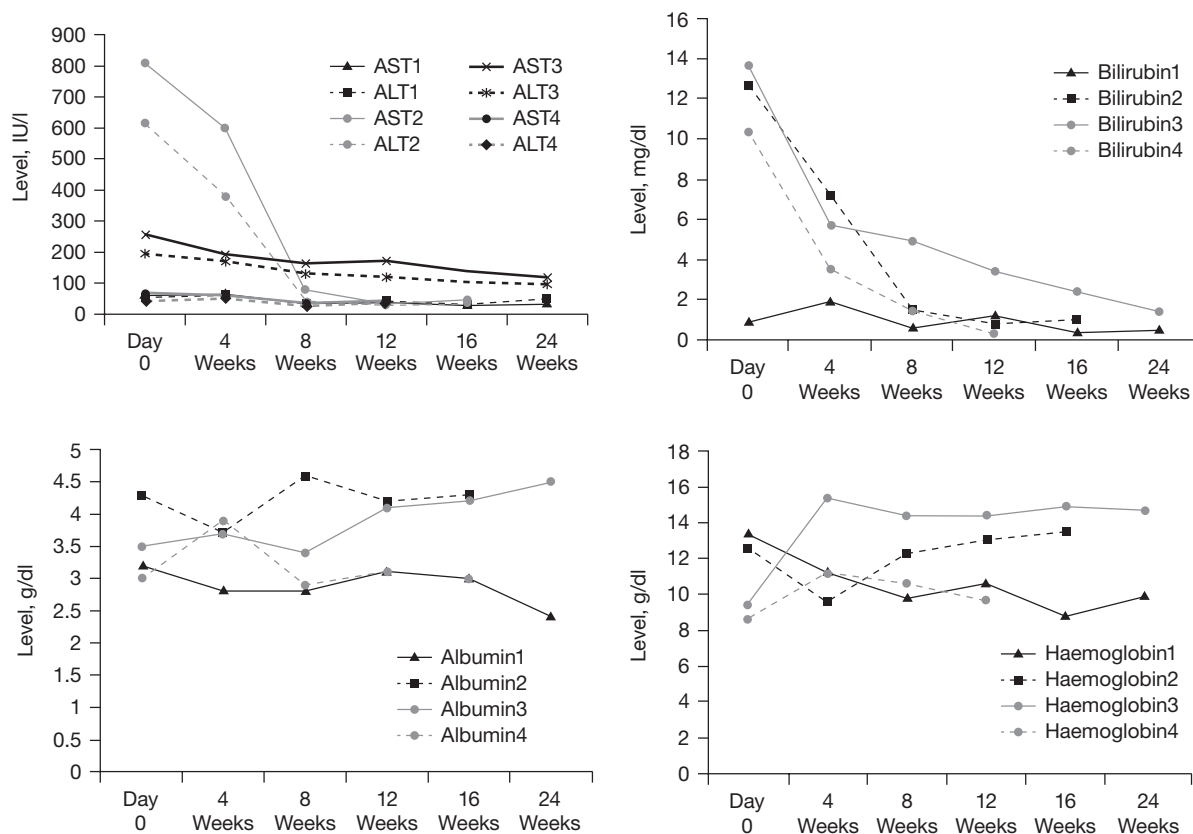
An 18-year-old female was diagnosed with decompensated autoimmune cirrhosis in August 2010. She was hospitalized with icterus for 6 months, ascites for 2 weeks and encephalopathy for 2 days. Investigations revealed haemoglobin of 7.1 g/dl, platelet count $102,000/\text{mm}^3$, serum bilirubin 11.3 mg/dl, AST 239 IU/l, ALT 77 IU/l, alkaline phosphatase 673 IU/l, serum albumin 2.2 g/dl, serum globulin 6.3 g/l and INR >4 . Hepatitis viral markers including HBsAg, IgM anti-HBc, IgM anti-HAV, total anti-HBc, IgM anti-HEV and HCV RNA were negative. ANA, ASMA, anti-LKM1 and anti-mitochondrial antibody (AMA) were also negative. She had grade II oesophageal varices. Triphasic abdominal CT suggested cirrhosis. Treatment with prednisolone (1 mg/kg/day) for 4 weeks was started, but her liver functions deteriorated (serum bilirubin 13.7 mg/dl, ALT 194 IU/l, alkaline phosphatase 1,275 IU/l, INR 2, serum albumin 3.4 g/dl with IV albumin infusion and serum globulin 6 g/dl). At the time, HEV RNA was detected in her sera in two consecutive samples. Prednisolone was discontinued and ribavirin 200 mg/day was started (a lower dose was given due to presence of severe anaemia). After 8 weeks, HEV RNA was undetectable and her liver functions improved (Figure 1). After 6 months of treatment, there was marked improvement in her liver functions with clinical remission and ribavirin was discontinued. She has remained stable over a post-treatment period of 6 months without relapse of HEV infection.

Case 4

The patient was a 50-year-old male who presented with jaundice over 8 weeks and ascites associated with intermittent fever over 4 weeks. At admission, he had moderate ascites without hepatosplenomegaly. His bilirubin was 14.1 mg/dl, ALT 44 IU/l and INR 1.82. His IgM anti-HEV was positive and HEV RNA titres were 1.2×10^5 copies/ml. HBsAg, anti-HCV, HCV RNA, HBV DNA, ANA, anti-LKM1, ASMA and AMA were not detected in his sera. He had low-grade varices and he also had pneumonia at admission, which responded to broad-spectrum antibiotics. He was given ribavirin 600 mg/day with a provisional diagnosis of HEV-induced ACLF. Over the next 12 weeks, he became HEV-RNA-negative. His jaundice improved, ascites disappeared, he became afebrile and his appetite improved. His LFTs showed bilirubin of 0.3, ALT of 36 IU/l and serum albumin of 3.1 g/dl. Post-treatment follow-up data is not available.

Clinical and biochemical events after starting ribavirin treatment for each of the four cases are shown in Figure 1 and in Table 1.

Figure 1. Trends in AST, ALT, bilirubin, albumin and haemoglobin levels following treatment with ribavirin in four HEV ACLF patients



The numbers 1, 2, 3 and 4 against each of the laboratory parameters denote the corresponding values in cases 1, 2, 3 and 4, respectively. 'Day 0' is the time at which ribavirin therapy was started. The follow-up of 24 weeks for cases 1, 2 and 3, and 12 weeks for case 4 is shown. Values are expressed in IU/l for aspartate aminotransferase (AST) and alanine aminotransferase (ALT), g/dl for serum albumin and haemoglobin, and mg/dl for serum bilirubin. ACLF, acute on chronic liver failure; HEV, hepatitis E virus.

Discussion

Hepatitis E is a frequent cause of acute hepatitis, acute liver failure (ALF) and ACLF in hyperendemic regions for HEV [1]. Although acute hepatitis E is self-limiting with complete clinical, biochemical and virological recovery in 95–98% of cases [1], patients with HEV-associated ALF and ACLF have a high mortality rate of 60–70% [2–7,14]. Medical therapeutic options in such patients are only supportive and liver transplantation is the only effective treatment. The present report indicates that ribavirin could eradicate HEV viraemia with subsequent improvement in clinical as well as biochemical liver function, which contributed to the survival of all four patients; therefore, ribavirin may be an effective medical therapeutic option in HEV-induced ACLF.

Four important questions need to be addressed before ribavirin could be established and recommended as the

therapy of choice in HEV ACLF. These issues would include: what is the natural history of HEV viraemia in patients with ACLF and whether antiviral treatment shortens the viraemia period? Is HEV treatment with ribavirin efficient in terms of disease outcome and survival in HEV ACLF? Is treatment with ribavirin in HEV ACLF safe? What is the possible mechanism of action of ribavirin in eradicating HEV infection in such patients? Adequate data on the issues raised by the above questions are not available yet in literature. In the following paragraph, we address these issues based on an available evidence.

Long-term cohort follow-up assessing the status of HEV viraemia in patients with HEV ACLF during its natural course is not available in current literature. All studies on HEV ACLF to-date focus on the high short-term mortality [1–4] and have used IgM antibody against the fusion protein of ORFs 2 and 3 (IgM

Table 1. Clinical course and treatment outcomes in four HEV ACLF patients treated with ribavirin

Case number	Dose of ribavirin, mg/day	Duration of therapy, weeks	Time to first documentation of HEV clearance, weeks	Side effects	Duration of follow-up after stopping ribavirin, months	Relapse	Comments
1	600 ^a	7	4	None	6	No	Treatment stopped early as the patient developed haematuria.
2	400	3	3	Anaemia	6	No	Lower dose given initially with plan to step-up the dose later. Treatment was stopped early after discussing with the patient as he had a decrease of haemoglobin of 3 g/dl over 3 weeks.
3	200	24	8	None	6	No	Treatment started at a lower dose due to presence of severe anaemia (haemoglobin 7.2 g/dl) at baseline.
4	600 ^a	12	4	None	NA	NA	Completed 12 weeks of therapy, scheduled for follow-up.

^a12 mg/kg/day. ACLF, acute on chronic liver failure; HEV, hepatitis E virus; NA, not applicable (as the post-treatment follow-up is not available presently).

anti-HEV) to diagnose HEV superinfection [14]. However, in 2007 we used detection of HEV RNA in sera of patients to diagnose HEV ACLF [7]. Among 42 ACLF patients in this study, 21 (50%) had detectable HEV RNA and in all but one, HEV RNA was detected at or beyond 4 weeks of the onset of illness. This suggests that HEV viraemia in the 21 patients was prolonged in comparison to immunocompetent individuals without pre-existing chronic liver disease, in whom the HEV viraemia lasted for approximately 2 weeks [1,14]. In these immunocompetent patients, the disease is self-limiting with complete clinical and biochemical remission in 4–6 weeks. By contrast, the natural course of ACLF is associated with rapid deterioration of liver function resulting in high mortality. Among the 21 patients with HEV ACLF reported in our earlier study, 13 (65%) died within 4 weeks and all died within 12 months. Péron *et al.* [11] reported HEV ACLF in two patients with underlying alcoholic liver disease who were treated with ribavirin. In them, the interval between ribavirin treatment and disappearance of HEV RNA was approximately 4 weeks. The existing evidence trends support persistent viraemia in HEV ACLF.

The preliminary evidence in all these reported cases of HEV ACLF would indicate that ribavirin eradicated the HEV in these ACLF patients (four cases described in the present study and two cases described in an earlier study [11]). Subsequent clinical and biochemical improvement was also observed, with 100% survival that seems unlikely to have happened spontaneously,

particularly when the previously reported patients with HEV ACLF without treatment had very high mortality.

Efficacy of short-course ribavirin against HEV leading to undetectable viraemia has been documented in patients with chronic HEV viraemia persisting for >6 months in post-transplant immunosuppressed patients [8–10].

This preliminary evidence provides the *prima facie* evidence that HEV viraemia in HEV ACLF may be prolonged and ribavirin might have shortened the duration of viraemia, resulting in alteration in the natural course with survival benefit. These observations may establish the rationale to conduct randomized control trials using ribavirin in HEV ACLF.

The experience of ribavirin treatment in HEV ACLF is limited to the four cases included in the present report and two patients of HEV ACLF described by Péron *et al.* [11]. The only side effect documented was anaemia (a well-known side effect of ribavirin) in one patient included in the present report. Furthermore, ribavirin treatment in patients with chronic HEV infection was found to be safe [8–10].

Ribavirin is a guanosine analogue effective against both DNA and RNA viruses. However, the exact mechanism of its action is unclear. Inhibition of inosine phosphate dehydrogenase by ribavirin with consequent inhibition of conversion of inosine phosphate to guanosine (leading to depletion of guanosine) may decrease synthesis of RNA-dependent RNA polymerase (RdRp) of HEV located in its ORF1 region [15]. Furthermore, ribavirin may affect guanosine-mediated capping of

Table 2. Comparative data of studies and case reports that have used ribavirin treatment in patients with acute or acute on chronic HEV infections

Reference	Patient, <i>n</i>	Dose of ribavirin, mg/day	Duration of therapy, weeks	Time to first documentation of HEV clearance, weeks	Side effect	Duration of follow-up	Relapse, <i>n</i>	Genotype	Comments
[8]	2	600–800	12	4	Anaemia requiring dose modification in one patient	8–12 weeks	None	3	Chronic HEV infection in post-transplant/ immunosuppressed setting
[9]	8	400–800	12	2–8	Anaemia requiring transfusion and dose modification in two patients	24 weeks in 6 patients	2 (over 24 weeks)	3	Chronic HEV infection in post-renal transplant setting
[10]	1	800	12	4	None	16 weeks	None	3	Chronic HEV infection in post-heart–lung transplant setting
[11]	2	200 mg on alternate days to 1,000 g/day	1.5–12	4	Anaemia in one patient	Not mentioned	None	3	HEV ACLF
Present study	4	200–600	3–24	3–8	Anaemia requiring treatment interruption in one patient	0–6 months	None	Not done, likely genotype 1	HEV ACLF

ACLF, acute on chronic liver failure; HEV, hepatitis E virus.

messenger RNA, which is essential for RNA stability. HEV genome is capped and polyadenylated and therefore interference with capping of HEV genome by ribavirin may cause HEV RNA destruction [16,17]. Ribavirin is converted to ribavirin mono-, di- and triphosphates in the human cell and they are all inhibitors of RdRp [18]. Ribavirin has also been documented to enhance the T-cell-mediated antiviral immunity by switching host T-cell phenotype from Th2 to Th1 [19]. Therefore, ribavirin in HEV ACLF might be acting through multiple mechanisms. Furthermore, ribavirin is likely to act against all the genotypes of HEV. To-date, HEV genotyping is done by sequencing the ORF2 region of HEV [1,14]; however, ribavirin is likely to act against RdRp located in ORF1 region and its heterogeneity across genotypes has not yet been documented.

Recently, chronic HEV infection causing chronic hepatitis was reported among immunosuppressed liver and renal transplant patients [9]. Kamar *et al.* [9] reported that 45.7% of 35 post-renal transplant patients developed chronic HEV infection (HEV viraemia for >6 months with increased liver enzymes). Such patients could be effectively treated with ribavirin for 12 weeks in doses similar to that used in the treatment of chronic hepatitis C (800 mg/day; Table 2) without any serious adverse events. Chronic infections are likely to become a significant problem especially in the post-transplant setting. Liver transplants are increasingly

being done in developing countries like India, which are hyperendemic for HEV; the present study highlights further importance in providing a possible therapeutic agent to treat such patients. In summary, ribavirin may be an effective and safe therapy option in HEV ACLF; however, further appropriate study is necessary.

Acknowledgements

RG contributed to acquisition of data, analysis and interpretation of data and the drafting of manuscript. AK contributed to the drafting of manuscript and the critical revision of the manuscript. SKP contributed technical support during serological assays and PCR. SBP contributed to technical support in the interpretation of all radiological images and radiology-guided interventions (TACE). SKA contributed to the study concept and design, study supervision and to the critical revision of the manuscript.

Disclosures statement

The authors declare no competing interests.

References

1. Acharya SK, Panda SK, Hepatitis E. Virus: epidemiology, diagnosis, pathology and prevention. *Trop Gastroenterol* 2006; 27:63–68.

2. Sarin SK, Kumar A, Almeida JA, *et al.* Acute-on-chronic liver failure: consensus recommendations of the Asian Pacific Association for the study of the liver (APASL). *Hepatol Int* 2009; **3**:269–282.
3. Ramachandran J, Eapen CE, Kang G, *et al.* Hepatitis E superinfection produces severe decompensation in patients with chronic liver disease. *J Gastroenterol Hepatol* 2004; **19**:134–138.
4. Monga R, Garg S, Tyagi P, Kumar N. Superimposed acute hepatitis E infection in patients with chronic liver disease. *Indian J Gastroenterol* 2004; **23**:50–52.
5. Kumar A, Aggarwal R, Naik SR, Saraswat V, Ghoshal UC, Naik S. Hepatitis E virus is responsible for decompensation of chronic liver disease in an endemic region. *Indian J Gastroenterol* 2004; **23**:59–62.
6. Kc S, Mishra AK, Shrestha R. Hepatitis E virus infection in chronic liver disease causes rapid decompensation. *JNMA J Nepal Med Assoc* 2006; **45**:212–215.
7. Acharya SK, Sharma PK, Singh R, *et al.* Hepatitis E virus (HEV) infection in patients with cirrhosis is associated with rapid decompensation and death. *J Hepatol* 2007; **46**:387–394.
8. Mallet V, Nicand E, Sultanik P, *et al.* Brief communication: case reports of ribavirin treatment for chronic hepatitis E. *Ann Intern Med* 2010; **153**:85–89.
9. Kamar N, Rostaing L, Abravanel F, *et al.* Ribavirin therapy inhibits viral replication in patients with chronic hepatitis E virus infection. *Gastroenterology* 2010; **139**:1612–1618.
10. Chaillon A, Sirinelli A, De Muret A, Nicand E, d'Alteroche L, Goudeau A. Sustained virologic response with ribavirin in chronic hepatitis E virus infection in heart transplantation. *J Heart Lung Transplant* 2011; **30**:841–843.
11. Péron JM, Dalton H, Izopet J, Kamar N. Acute autochthonous hepatitis E in western patients with underlying chronic liver disease: a role for ribavirin? *J Hepatol* 2011; **54**:1323–1324.
12. Aggarwal R, Naik S. Epidemiology of hepatitis E: current status. *J Gastroenterol Hepatol* 2009; **24**:1484–1493.
13. Jameel S, Durgapal H, Habibullah CM, Khuroo MS, Panda SK. Enteric nonA, nonB hepatitis: epidemics, animal transmission and hepatitis E virus detection by the polymerase chain reaction. *J Med Virol* 1992; **37**:263–270.
14. Acharya SK, Panda SK. Hepatitis E: water, water everywhere - now a global disease. *J Hepatol* 2011; **54**:9–11.
15. Gish RG. Treating HCV with ribavirin analogues and ribavirin-like molecules. *J Antimicrob Chemother* 2006; **57**:8–13.
16. Bougie I, Bisailon M. The broad spectrum antiviral nucleoside ribavirin as a substrate for a viral RNA capping enzyme. *J Biol Chem* 2004; **279**:22124–22130.
17. Graci JD, Cameron CE. Therapeutically targeting RNA viruses via lethal mutagenesis. *J Future Virol* 2008; **3**:553–566.
18. Cannon NA, Donlin MJ, Mayes LM, Lyra AC, Di Bisceglie AM, Tavis JE. Evidence for action of ribavirin through hepatitis C virus RNA polymerase. *J Viral Hepat* 2009; **16**:595–604.
19. Tsai SL, Sheen TI, Chien RN, *et al.* Activation of TH1 immunity is common immune mechanism for successful treatment of hepatitis B and C: treatment assay and therapeutic implications. *J Biomed Sci* 2003; **10**:120–135.

Accepted 29 November 2011; published online 16 August 2012