

Original Article

Internal jugular vein: Peripheral vein adrenocorticotrophic hormone ratio in patients with adrenocorticotrophic hormone-dependent Cushing's syndrome: Ratio calculated from one adrenocorticotrophic hormone sample each from right and left internal jugular vein during corticotrophin releasing hormone stimulation test

Sachin Chittawar, Saptarshi Bhattacharya, Jai Prakash Sahoo, Siva Prakash, Ashu Seith Bhalla¹, Devasenathipathy Kandasamy, Arundeeep Arora, Nandita Gupta, Nikhil Tandon, Ravinder Goswami, Rajesh Khadgawat, Viveka P. Jyotsna, Ashish Kumar Karak², Chandra Sekhar Bal³, Ravindra Mohan Pandey⁴, Guresh Kumar, Ariachery C. Ammini

Departments of Endocrinology, ¹Radiology, ²Pathology, ³Nuclear Medicine and ⁴Biostatistics, All India Institute of Medical Sciences, New Delhi, India

ABSTRACT

Background: Demonstration of central: Peripheral adrenocorticotrophic hormone (ACTH) gradient is important for diagnosis of Cushing's disease. **Aim:** The aim was to assess the utility of internal jugular vein (IJV): Peripheral vein ACTH ratio for diagnosis of Cushing's disease. **Materials and Methods:** Patients with ACTH-dependent Cushing's syndrome (CS) patients were the subjects for this study. One blood sample each was collected from right and left IJV following intravenous hCRH at 3 and 5 min, respectively. A simultaneous peripheral vein sample was also collected with each IJV sample for calculation of IJV: Peripheral vein ACTH ratio. IJV sample collection was done under ultrasound guidance. ACTH was assayed using electrochemiluminescence immunoassay (ECLIA). **Results:** Thirty-two patients participated in this study. The IJV: Peripheral vein ACTH ratio ranged from 1.07 to 6.99 ($n = 32$). It was more than 1.6 in 23 patients. Cushing's disease could be confirmed in 20 of the 23 cases with IJV: Peripheral vein ratio more than 1.6. Four patients with Cushing's disease and 2 patients with ectopic ACTH syndrome had IJV: Peripheral vein ACTH ratio less than 1.6. Six cases with unknown ACTH source were excluded for calculation of sensitivity and specificity of the test. **Conclusion:** IJV: Peripheral vein ACTH ratio calculated from a single sample from each IJV obtained after hCRH had 83% sensitivity and 100% specificity for diagnosis of CD.

Key words: Cushing's disease, cushing's syndrome, internal jugular vein sampling

Access this article online

Quick Response Code:



Website:
www.ijem.in

DOI:
10.4103/2230-8210.107843

INTRODUCTION

Diagnosis and differential diagnosis of Cushing's syndrome (CS) is one of the most difficult problems in the field of clinical endocrinology.^[1,2] Adrenocorticotrophic hormone (ACTH)-dependent CS is, most often, caused by ACTH secreting pituitary adenomas [Cushing's

Corresponding Author: A C Ammini, Professor and Head, Department of Endocrinology, All India Institute of Medical Sciences, New Delhi, India.
E-mail: aca433@yahoo.com

disease (CD)] that are usually small.^[3,4] Contrast-enhanced dynamic magnetic resonance imaging (MRI) has improved the detection rate for pituitary adenomas causing CD. However, possibility of incidental pituitary microadenoma in a patient with CS further complicates the problem.^[4] Ectopic ACTH secretion (from a non-pituitary tumor) is responsible for about 10-15% of cases of ACTH-dependent CS. Therefore, it is important to document central: Peripheral ACTH gradient to differentiate CD from ectopic ACTH syndrome (EAS). Bilateral inferior petrosal sinus sampling (BIPSS) with corticotrophin releasing hormone (CRH) stimulation is currently the gold standard for the diagnosis CD.^[5] BIPSS is not widely available because it is technically demanding. Although rare, the procedure is associated with serious neurological complications and venous and pulmonary thromboembolism.^[6]

We studied the feasibility of direct ultrasound-guided internal jugular vein (IJV) sampling for ACTH in a small cohort of patients with ACTH-dependent CS.^[7] An IJV: Peripheral vein gradient for ACTH was observed in two-thirds of patients with CD. Here, we report the results of CRH stimulated IJV: Peripheral vein ACTH ratio in patients with ACTH-dependent CS.

MATERIALS AND METHODS

Patients with ACTH-dependent CS were the subjects for this study. Children less than 10 years of age, patients with pituitary macroadenoma, and very ill patients (patients with multiple vertebral fractures, severe myopathy, etc.) were excluded.

IJV ACTH sample collection was done in the ultrasound room in the Radiology department. Basal samples were collected from a previously placed IV cannula at cubital vein at 5 and 0 min. One hundred micrograms of human CRH (hCRH) (Ferring) was given through the peripheral IV cannula. IJV blood collection was done under ultrasound guidance (direct puncture) by a dedicated radiologist. Blood was collected with a 21-G needle at the level of mandible with the patient in supine position as described previously.^[8] Needle was inserted keeping the tip toward the medial wall of IJV. Blood was collected at 3 and 5 min following intravenous hCRH from right and left IJV, respectively. Simultaneously (with IJV sample), peripheral vein samples were also collected at 3 and 5 min. The patient was asked to do Valsalva maneuver during IJV sampling.

Blood samples were collected in pre-chilled plastic tubes containing ethylenediaminetetraacetic acid (EDTA) and were sent to laboratory immediately. ACTH was assayed using electrochemiluminescence immunoassay (ECLIA).

Two monoclonal antibodies specific for ACTH 9-12 and for the C-terminal region (ACTH 36-39) were used for ACTH assay.^[9] The measuring range for this assay was 1-2000 pg/ml. Ratios of IJV: Peripheral vein ACTH were estimated for right and left IJV (i.e., right IJV ACTH/simultaneously collected peripheral vein ACTH and left IJV ACTH/simultaneously collected peripheral vein ACTH) separately. From these two values, the higher number was used for analysis.

This being a pilot study, a sample size of 30 was planned based on the number of subjects likely to be available over a 2-year period. The study protocol was approved by the institutional ethics committee. Informed consent was taken from patients (parents in case of subjects less than 18 years of age, in addition to assent from the patient).

RESULTS

This study was carried out over a period of 26 months starting from March 2010. During this period, 52 patients (37 females and 15 males) were diagnosed to have CS, 4 were ACTH independent (adrenal adenoma), and 48 were ACTH dependent. Among the ACTH-dependent patients, four had pituitary macroadenoma, six patients were too ill (all patients had multiple vertebral fractures and severe myopathy) to undergo the procedure, one patient did not give consent (a 13-year-old boy who was apprehensive about the procedure), and five had not completed investigations/treatment. Thirty-two patients [23 females and 9 males, age 12-55 years (mean \pm SD, 26 \pm 11)] participated in this study. Details of these patients are given in Table 1. Eleven of these 32 patients had more than 80% suppression of plasma cortisol on high dose dexamethasone suppression test (HDDST). MRI (contrast-enhanced dynamic scans) revealed lesions in 19 of these 32 patients, with size ranging from 2 to 8 mm. Five lesions were more than 5 mm in size. Two patients were diagnosed to have EAS with computed tomography (CT) and (68)Ga-DOTANOC positron emission tomography-computed tomography (PET-CT).

The IJV: Peripheral ACTH ratio ranged from 1.07 to 6.99 ($n = 32$). It was more than 1.6 in 23 (more than 3 in 11) patients. CD could be confirmed in 16 on histopathology; 4 are in remission following pituitary surgery although tumor could not be identified on histopathology. Two young women (cases 21 and 22) underwent pituitary exploration twice, but no tumor could be identified at surgery or histopathology. Case 23 underwent bilateral total adrenalectomy as life-saving procedure. There were nine patients who had IJV: Peripheral vein ACTH ratio less than 1.6. Three of them had corticotroph tumor confirmed on histopathology, EAS could be confirmed in two patients (one thymic carcinoid and another pulmonary carcinoid), and the other four patients underwent bilateral

Table 1: Profile of patients

Patient ID, age, sex	MRI size of lesion	HDDST % sup.	IJV: P vein ACTH ratio	% ACTH rise	% Cortisol rise	Diagnosis	Tumor	Outcome
Arch, 36, F	7 mm	25	4.43	454	151	CD	+	Pituitary surgery twice, Gamma Knife and total adrenalectomy
Kanc, 14, F	2 mm	75	3.12	68	32	CD	+	Remission
Kulv, 21, F	5 mm	93	5	145	102	CD	+	Remission
Love, 30, F	8 mm	94	6.23	247	93	CD	+	Remission
Meer, 55, F	6 mm	80	2.18	97.7	35.5	CD	+	Remission
Mehr, 19, M	3 mm	47	3.84	73	13	CD	-	Remission
Neelam, 18, F	3 mm	58	3.8	500	37	CD	+	Persisting disease
Parv, 46, F	3 mm	92	6.99	156	67	CD	+	Remission
Prat, 15, F	3 mm	90	3.04	1218	409	CD	+	Remission
Rlak, 13, F	N	89	6.82	819	165	CD	-	Remission
Raji, 45, F	5 mm	81	3.9	69.6	16.3	CD	+	Pituitary surgery followed by total adrenalectomy
Rath, 35, F	6 mm	78	1.86	52	36	CD	+	Remission
Sanj, 32, M	N	19	3.8	868	93	CD	-	Remission
Sapn, 32, F	6 mm	45	3.7	114	34.5	CD	+	Remission
Saro, 36, F	5 mm	93	1.65	135	25	CD	+	Remission
Saur, 16, M	4 mm	88	2.9	304	19.6	CD	+	Remission
Sint, 22, F	N	90	1.81	72	0	CD	-	Remission
Tanz, 18, F	N	48	3.23	386	37	CD	+	Remission
Pram, 31, F	3 mm	45	1.8	91	13	CD	+	Post-op cortisol low
Mohq, 40, M	4 mm	21	5	463	31	CD	?	Post-op death
Hars, 20, F	N	83	4.26	239	61	UK	-	Persisting disease, pituitary surgery twice
Yogi, 30, F	N	54	2.94	79	37	UK	-	Pituitary surgery twice and total adrenalectomy
Sonu, 12, M	N	32	1.67	26.5	16.4	UK	NA	Adrenalectomy, 2 months
Anku, 25, M	3 mm	63	1.42	99	21	CD	+	Pituitary surgery twice, remission
Obed, 16, M	N	55	1.37	174	21.8	CD	+	Remission
Vija, 13, M	3 mm	46	1.09	502	38	CD	+	Remission
Pram, 14, F	N	59	1.07	36	3.5	EAS	TC	Remission
Usha, 50, F	N		1.46	3	12	EAS	LC	Hypocortisolemic
Yasm, 25, F	3 mm	20	1.49	68	0	CD	NA	ACTH high following adrenalectomy
Dhir, 23, M	N	47	1	23	2	UK	NA	ACTH normal at 1 year post adrenalectomy
Shai, 17, F	N	41	1.24	247	33	UK	NA	ACTH normal 8 months post adrenalectomy
Shiv, 24, F	N	53	1.37	25	25.8	UK	NA	ACTH normal 8 months post adrenalectomy

TC: Thymic carcinoid, LC: Pulmonary carcinoid, N normal pituitary on MRI scan, UK occult ACTH source, NA not applicable, CD: Cushing's disease, EAS: Ectopic ACTH syndrome

total adrenalectomy as they had severe hypercortisolism and the test results were discordant.

Peripheral CRH stimulation test (using a cut-off of 50% rise for ACTH and $\geq 13\%$ for cortisol) showed positive test for the 23 cases with IJV: P vein ACTH ratio more than 1.6 (one patient who had no cortisol response showed a positive ACTH response and another had a positive cortisol response, while there was no ACTH response). There was a more heterogeneous pattern among those with IJV: P ratio less than 1.6. The three patients who had CD gave a positive response, while the two EAS patients showed negative response both for ACTH and cortisol. Of the four who underwent adrenalectomy, one had positive ACTH and cortisol response, one had positive ACTH response with negative cortisol response, one had negative ACTH response with positive cortisol response, and one was negative for both ACTH and cortisol.

Twenty-four of these 32 were CD (19 pituitary tumors with positive immunohistochemistry for ACTH, 4

remission after pituitary surgery, and 1 adrenalectomy) and 2 were EAS. Six patients were grouped under ACTH source unknown and are on follow-up. For calculation of sensitivity and specificity of the test (IJV: P ACTH ratio), these six cases were not included.

Taking IJV: Peripheral vein ACTH ratio > 1.6, this test showed 83% sensitivity with 100% specificity for diagnosing CD [Table 2]. Both the patients with EAS had lower ratios.

All patients tolerated the procedure well. Postoperatively, all the patients experienced CRH flushing, and five patients complained of local neck discomfort, which resolved spontaneously. There were no other adverse events during or following the procedure.

DISCUSSION

The present study was undertaken to assess the utility of IJV: Peripheral vein ACTH ratio for the diagnosis of

Table 2: Results of magnetic resonance imaging, high dose dexamethasone suppression test, and hCRH stimulated internal jugular vein: Peripheral vein adrenocorticotrophic hormone ratio

Test	Pituitary n=24	Ectopic n=02	Unknown n=06	Sensitivity	Specificity
MRI >5 mm	195	0	0	79	100
HDDST >80% suppression	10	0	1	41	100
HDDST >50% suppression	15	1	3	62	50
CRH IJV: P ratio ≥1.6	20	0	3	83	100
Ratio >3	14	0	1	58	100
CST as per ACTH >35%	24	1	3	100	50
CST as per ACTH >50%	24	0	3	100	100
CST as per cortisol >13%	22	0	5	91.6	100
CST as per cortisol >20%	17	0	4	70	100

For calculation of sensitivity and specificity, the unknown has been excluded CST, CRH stimulation test, ACTH: Adrenocorticotrophic hormone

CD. Ultrasound-guided direct venous puncture was used for blood collection from IJV. Samples were collected 3 and 5 min after intravenous hCRH administration, from right and left IJV, respectively, along with simultaneous peripheral vein sample. A single sample was collected from right IJV at 3 min and another sample was collected from the peripheral vein simultaneously. Similarly, a single sample was collected from the left IJV at 5 min, along with a sample from the peripheral vein at the same time. IJV: Peripheral vein ACTH ratio was calculated for both right and left IJV separately, and the higher number was taken as the ratio. Thirty-two patients (23 females and 9 males), with age ranging from 12 to 55 (mean ± SD 26 ± 11) years, were enrolled in this study.

The CRH stimulated IJV: Peripheral ACTH ratio ranged from 1.07 to 6.99. Eleven patients had IJV: Peripheral vein ACTH ratio equal to or more than 3, while 23 had ratio more than 1.6. Among the 23 with ratio more than 1.6, 20 had CD while the ACTH source could not be confirmed in 3. Among the nine patients with IJV: Peripheral vein ACTH ratio less than 1.6, four had CD, two had EAS, and the ACTH source could not be identified in three patients. Using a cut-off of 1.6, this test had a sensitivity of 83% with a specificity of 100% (CS cases with unknown ACTH source were excluded for calculation of sensitivity and specificity) for diagnosis of CD.

P. C. Scriba reported the first successful ACTH estimation in samples obtained from IJV in patients with ACTH-dependent CS in 1966.^[8] He had demonstrated IJV: Peripheral vein ratio 1.5 ± 0.15 in four out of five CD patients. There was absence of C: P gradient in three ectopic Cushing's patients. Since then, there have been several reports of IJV sampling.^[10-13] As noninvasive imaging techniques for diagnosis of pituitary tumor became available, this procedure became less popular.^[5]

Erickson, *et al.*^[14] compared Internal Jugular vein Sample (IJVS) with Inferior Petrosal Sinus Sample (IPSS) in 35 patients with

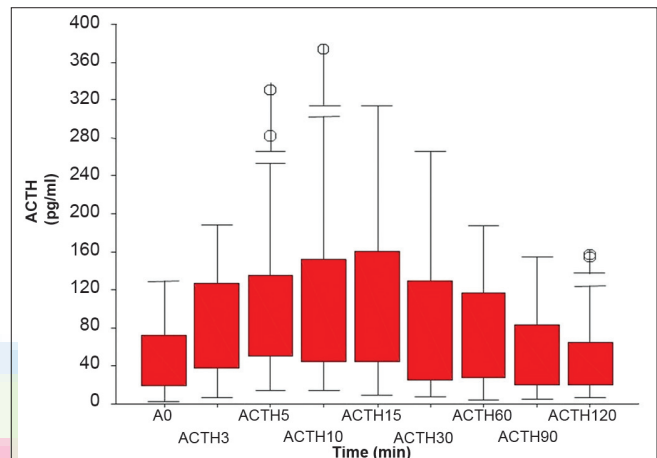


Figure 1: Adrenocorticotrophic hormone response (peripheral) to corticotrophin releasing hormone

ACTH-dependent CS (32 CD and 3 ectopic). Using the basal central: Peripheral ACTH ratio of >2, IJVS diagnosed 15 (47%) of the 32 patients with CD while 29 could be diagnosed with IPSS. When a lower cut-off (1.6) was used, the sensitivity increased to 86%. Ilias, *et al.*^[10] also compared IJVS with IPSS in patients with ACTH-dependent CS. ACTH values from IJVS were lower compared to IPSS, possibly due to venous dilution. Basal central: Peripheral ACTH ratio showed considerable overlap between patient groups, but with CRH stimulation, the sensitivity increased to 83% at 100% specificity. There were four patients with abnormal petrosal sinus anatomy and negative IPSS results in this study. JVS correctly identified pituitary source for ACTH hypersecretion in all these four patients. These studies have used retrograde venous catheterization through femoral vein (Seldinger's technique) for IJV sampling.

Ultrasound-guided IJV sampling is less invasive and can be done along with CRH stimulation test. In the present study, the peripheral CRH stimulation test correctly identified more CD patients, than the IJV: Peripheral vein ratio. The peak ACTH response was seen between 5 and 15 min in the peripheral vein samples [Figure 1]. The IJV samples were collected at 3 and 5 min after CRH administration.

Had these samples been collected later like at 7 and 10 min, they may have given a greater gradient and better sensitivity. It needs to be tested in more patients.

The main limitation of this study is the number of patients with unknown ACTH source. We have a final diagnosis in only 26 of the 32 cases. The other 6 (19%) cases will require further follow-up to identify the source of ACTH excess. Some of these may be CD, while others may have occult ectopic or non-neoplastic cause for hypercortisolism.^[15] Etiology of CS remains occult in about 10% of patients even after extensive investigations.^[5,16]

ACKNOWLEDGMENTS

Mr. Leslie George and Ms. Shiji, technologists in the Department of Endocrinology, are acknowledged for their help in hormonal assays.

REFERENCES

- Nieman LK, Oldfield EH, Wesley R, Chrousos GP, Loriaux DL, Cutler GB Jr. A simplified morning ovine corticotropin-releasing hormone stimulation test for the differential diagnosis of adrenocorticotropin-dependent Cushing's syndrome. *J Clin Endocrinol Metab* 1993;77:1308-12
- Newel Price J, Grossman AB. The differential diagnosis of Cushing's syndrome. *Ann Endocrinol (Paris)* 2001;62:173-9.
- Newel Price J, Bretagne X, Grossman AB, Nieman LK. Cushing's syndrome. *Lancet* 2006;367:1605-17.
- Hall WA, Luciano MG, Doppman JL, Patronas NJ, Oldfield EH. Pituitary resonance imaging in normal human volunteers: Occult adenomas in general population. *Ann Intern Med* 1994;120:817-20.
- Ilias I, Torpy DJ, Pacak K, Mullen N, Wesley RA, Nieman LK. Cushing's syndrome due to ectopic corticotrophin secretion: Twenty years experience at the National Institutes of Health. *J Clin Endocrinol Metab* 2005;90:4955-62.
- Oboubie K, Davies JS, Ogunko A, Scanlon MF. Venous thromboembolism following inferior petrosal sinus sampling in Cushing's disease. *J Endocrinol Invest* 2000;23:542-4.
- Sahoo JP, Seith A, Gupta N, Dwivedi S, Ammini AC. Internal jugular vein adrenocorticotrophic hormone estimation for diagnosis of adrenocorticotrophic hormone-dependent Cushing's syndrome: Ultrasound-guided direct jugular vein sample collection. *Indian J Endocrinol Metab* 2012;6:972-5.
- Scriba PC, Hacker R, Dieterle P, Kluge F, Hociheuser W, Schwarz K. ACTH –Bestimmungen in plasma aus dem Bulbus cranialis venae jugularis. *Klin Wochenschr* 1966;44:1393-8.
- Talbot JA, Kane JW, White A. Analytical and critical aspect of ACTH determination. *Ann Clin Biochem* 2003;40:453-71.
- Ilias I, Chang C, Pacak K, Oldfield EH, Wesley R, Doppman J, *et al.* Jugular venous sampling: An alternative to petrosal sinus sampling for the diagnostic evaluation of ACTH-dependent Cushing's syndrome. *J Clin Endocrinol Metab* 2004;89:3795-800.
- Drury PL, Ratter S, Tomlin S, Rees LH, Williams J, Dacie JE, *et al.* Experience with selective venous sampling in diagnosis of ACTH-dependent Cushing's syndrome. *Br Med J (Clin Res Ed)* 1982;284:9-12.
- Teramoto A, Nemoto S, Takakura K, Sasaki Y, Machida T. Selective venous sampling directly from cavernous sinus in Cushing's syndrome. *J Clin Endocrinol Metab* 1993;76:637-41.
- Doppman JL, Oldfield EH, Neiman LK. Bilateral sampling of the internal jugular vein to distinguish between mechanisms of ACTH-dependent Cushing's syndrome. *Ann Intern Med* 1998;128:33-6.
- Erickson D, Huston J 3rd, Young WF Jr, Carpenter PC, Wermers RA, Bonelli FS, *et al.* Internal jugular vein sampling in ACTH-dependent Cushing's syndrome: A comparison with inferior petrosal sinus sampling. *Clin Endocrinol (Oxf)* 2004;60:413-9.
- Biswas K, Goyal R, Ammini AC, Karak AK, Sarkar C, Mishra NK, *et al.* Recurrent lymphocytic hypophysitis in a woman 27 years after subtotal adrenalectomy for hypercortisolism possibly of autoimmune origin. *J Assoc Physicians India* 2005;53:1066-9.
- Kaltsas GA, Giannulis MG, Newell-price JD, Dacie JE, Thakkar C, Afshar F, *et al.* A critical analysis of the value of simultaneous IPSS in Cushing's disease and the occult ectopic ACTH syndrome. *J Clin Endocrinol Metab* 1999;84:487-92.

Cite this article as: Chittawar S, Bhattacharya S, Sahoo JP, Prakash S, Bhalla AS, Kandasamy D, *et al.* Internal jugular vein: Peripheral vein adrenocorticotrophic hormone ratio in patients with adrenocorticotrophic hormone-dependent Cushing's syndrome: Ratio calculated from one adrenocorticotrophic hormone sample each from right and left internal jugular vein during corticotrophin releasing hormone stimulation test. *Indian J Endocr Metab* 2013;17:128-32.

Source of Support: Nil, **Conflict of Interest:** None declared.